



# Tachycardia Evaluation and Management

Wilson King MD

Elizabeth Saarel MD

University of Utah

6/6/2011



# PreTest Question

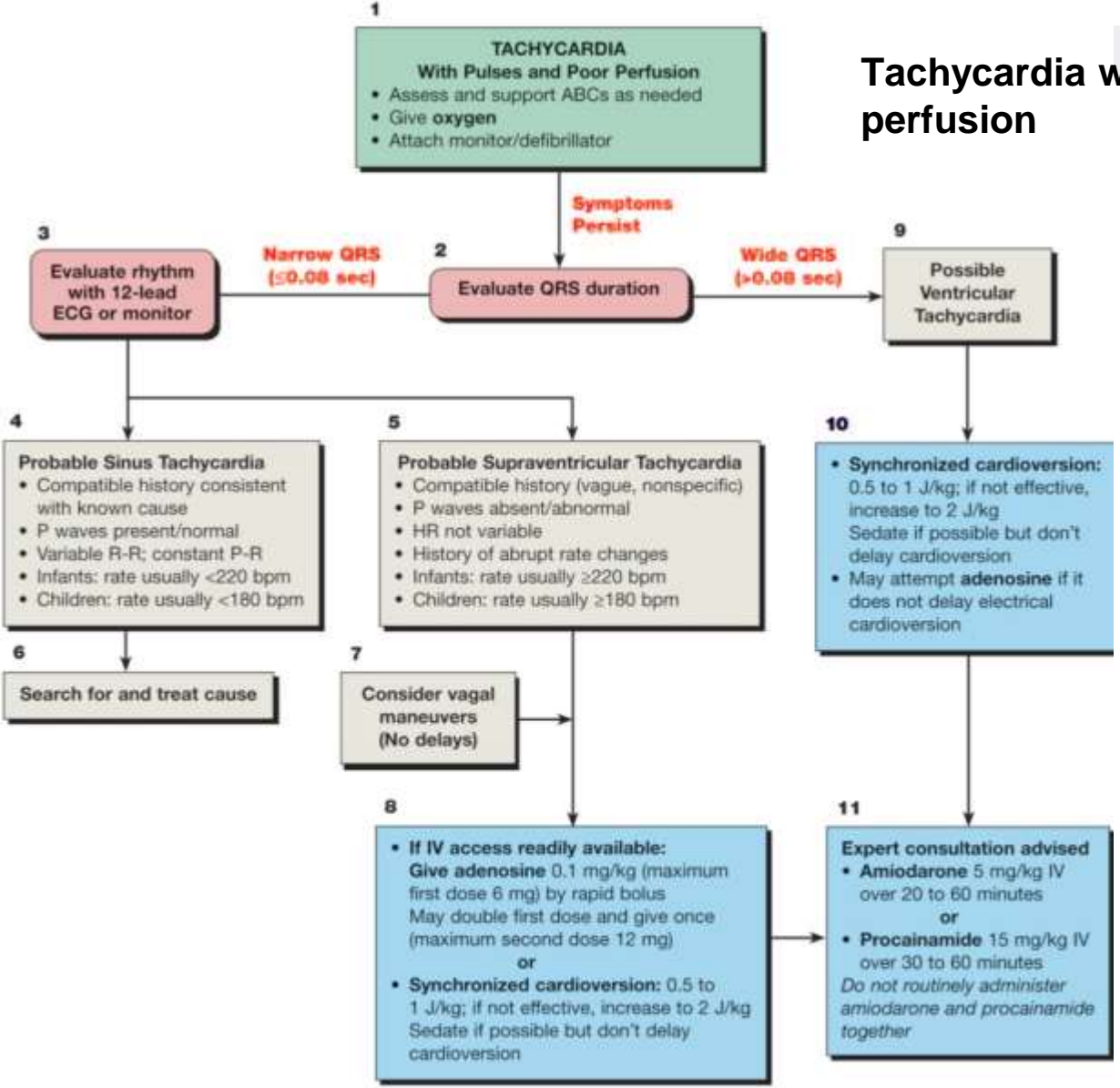
- You are called to the bedside of a patient with a heart rate of 250 bpm who looks comfortable. ECG shows narrow QRS with 1:1 P and QRS relationship. What should you do?
  - A. Bolus 20 cc/kg Normal Saline
  - B. Start Adenosine
  - C. Defibrillate
  - D. Synchronize cardioversion
  - E. Try vagal maneuvers
  
- You are called to the bedside of a patient with a heart rate of 300 bpm who has poor perfusion. ECG shows narrow QRS with 1:1 P and QRS relationship. Of the following, what is the best answer?
  - A. Obtain a chest x-ray
  - B. Start propranolol.
  - C. Defibrillate
  - D. Synchronize cardioversion
  - E. Tilt-table Test



# ECG Learning Objectives

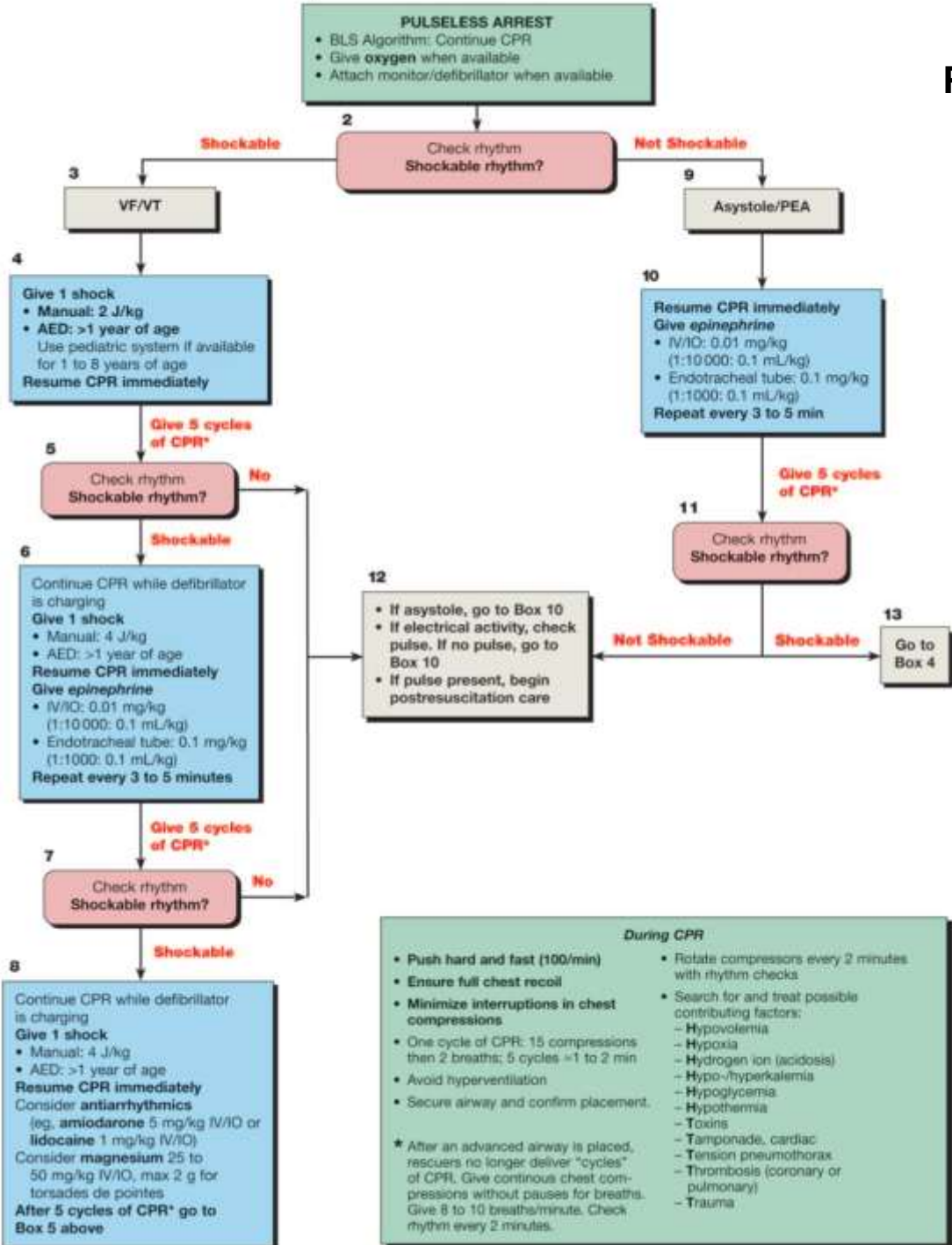
1. Recognize Tachycardias and initial management.
2. Recognize antegrade accessory pathways and potential complications.
3. Recognize ventricular tachycardia and apply PALS algorithm for pediatric pulseless arrest.

# Tachycardia with pulses and poor perfusion



During Evaluation	Treat possible contributing factors:
• Secure, verify airway and vascular access when possible	- Hypovolemia
• Consider expert consultation	- Hypoxia
• Prepare for cardioversion	- Hydrogen ion (acidosis)
	- Hypo-/hyperkalemia
	- Hypoglycemia
	- Hypothermia
	- Toxins
	- Tamponade, cardiac
	- Tension pneumothorax
	- Thrombosis (coronary or pulmonary)
	- Trauma (hypovolemia)

# Pulseless Arrest Algorithm



**During CPR**

- Push hard and fast (100/min)
- Ensure full chest recoil
- Minimize interruptions in chest compressions
- One cycle of CPR: 15 compressions then 2 breaths; 5 cycles = 1 to 2 min
- Avoid hyperventilation
- Secure airway and confirm placement.
- Rotate compressors every 2 minutes with rhythm checks
- Search for and treat possible contributing factors:
  - Hypovolemia
  - Hypoxia
  - Hydrogen ion (acidosis)
  - Hypo-/hyperkalemia
  - Hypoglycemia
  - Hypothermia
  - Toxins
  - Tamponade, cardiac
  - Tension pneumothorax
  - Thrombosis (coronary or pulmonary)
  - Trauma

\* After an advanced airway is placed, rescuers no longer deliver "cycles" of CPR. Give continuous chest compressions without pauses for breaths. Give 8 to 10 breaths/minute. Check rhythm every 2 minutes.

# Pick a Case


Case I

Case II

Case III

Case IV

To Summary  
and  
Questions





# Case #1

It is Sunday at 3:30pm, and you are just finishing your notes on service. You are paged by the emergency room who notices a 1 day old former term infant has a heart rate about 240 beats per minute. The infant's respiratory rate is unlabored, oxygen saturations are 92%, and you can't hear a murmur.

The infant does not appear to be in any distress. What is your next step?

# Case #1

## 1. Assess the patient

*(Is the patient stable?)*

- Airway
- Breathing
  - Tachypnea
- Circulation
  - Pulses, Perfusion
  - Heart Rate
  - Blood pressure

## Vital Ranges

Age	Heart Rate	Blood Pressure	Respiratory Rate
Premature	120-170	55-75/35-45	40-70
0-3 mo	100-150	68-85/45-55	35-55
3-6 mo	90-120	70-90/50-65	30-45
6-12 mo	80-120	80-100/55-65	25-40
1-3 yrs	70-110	90-105/55-70	20-30
3-6 years	65-110	95-110/60-75	20-25
6-12 yrs	60-95	100-120/60-75	14-22
12 yrs	55-85	110-135/68-85	12-18



# Case #1

## 1. Assess the patient

*(Is the patient stable?)*

- Airway
- Breathing
  - Tachypnea
- Circulation
  - Pulses, Perfusion
  - Heart Rate
  - Blood pressure

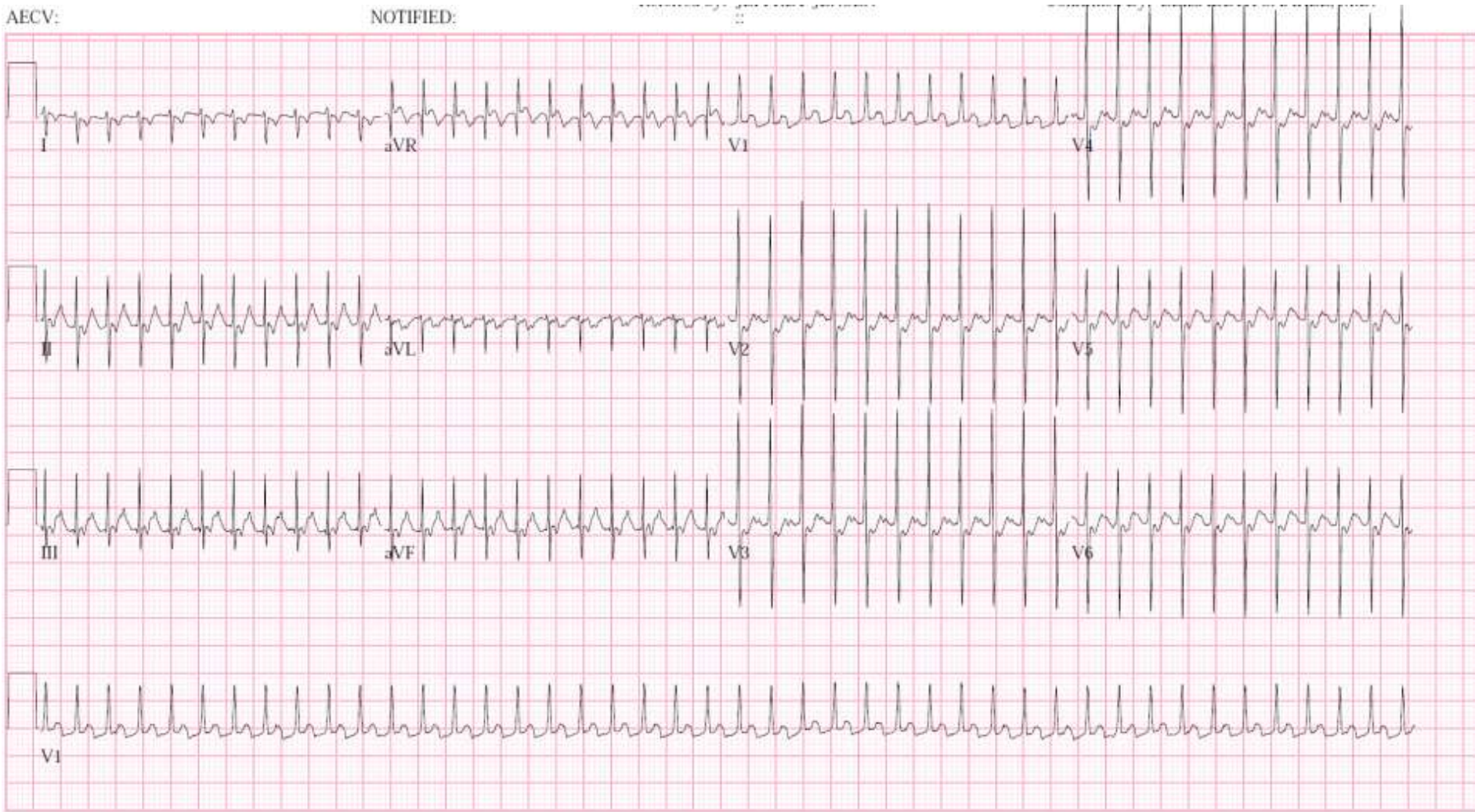
## 2. ECG

### Systolic Hypotension Criteria

Age	Systolic BP
0-30 days	<60
1 mo-1yr	<=70
> 1 year	70+ 2 x Age in years

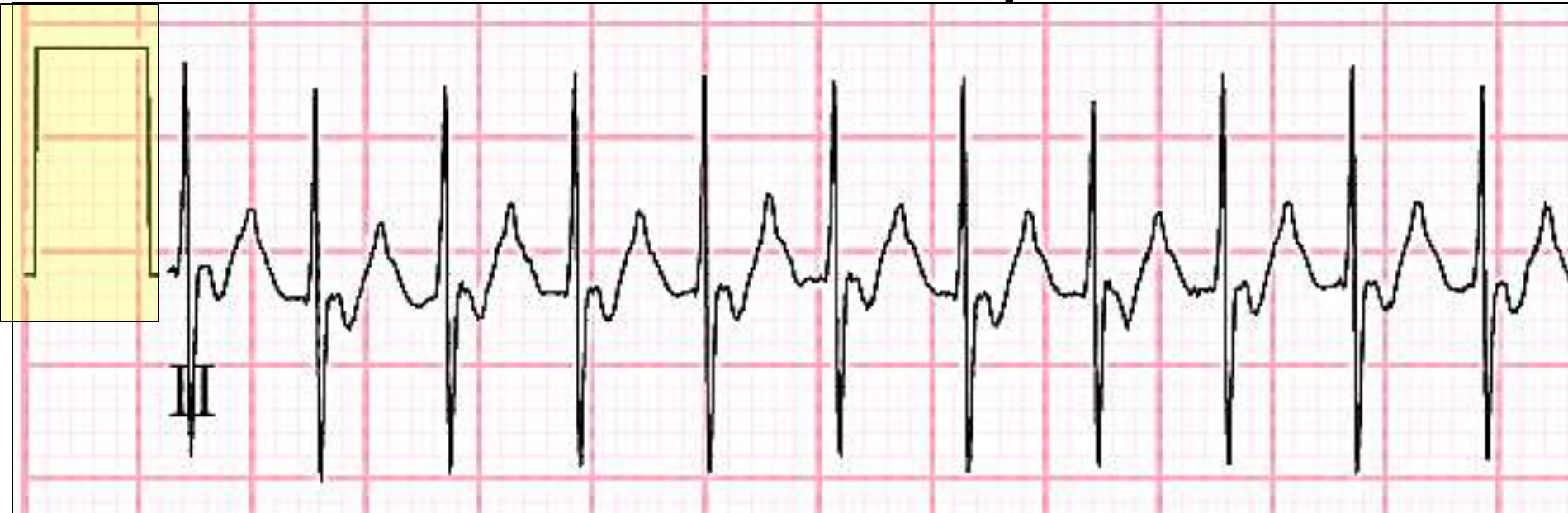# Case I

## Term infant:



# Case I

## Term infant: Basic interpretation



### •Is the ECG full standard?

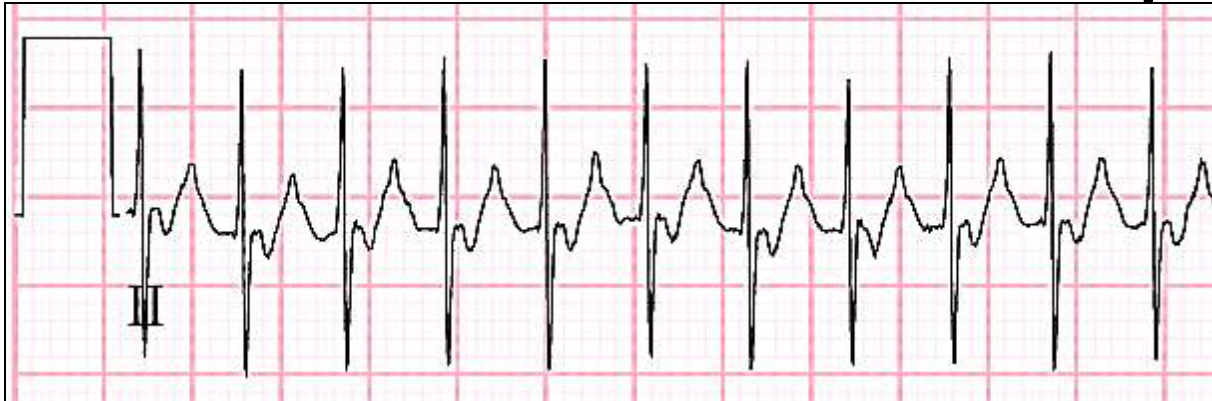- Yes, this ECG is full standard. If the initial rectangle is 2 large boxes high, that means the height of each small box (1 mm) = 1 millivolt, and the height of each large box (5 mm) = 5 millivolts.
- If the initial rectangle was 1 large box high, that would indicate the ECG was half standard, meaning the height of 1 small box (1 mm mark) = 2 millivolts, and the height of one big box (5mm) = 10 millivolts.
- Sometimes, one may see “a step” with a 2 box high rectangle next to a 1 box high rectangle. This means the limb leads are full standard and the precordial leads are half standard.

### •What is the speed of the paper?

- Standard speed is 25 mm/second.
- This means one little box (1mm) equals .04 seconds, and one large box (or five little boxes) equals 0.2 seconds.

# Case I

## Term infant: Basic interpretation



- Calculating rate (assuming regularity.. There are many ways to do this).
  - Method 1 -  $60/R-R$  interval (ie.  $60/0.24$  seconds = 250 beats per minute)
  - Method 1.1–  $60,000/R-R$  interval (ie.  $60,000/240$  milliseconds = 250 beats per minute) – **good method and how to think like an electrophysiologist.**
  - Method 2 -  $1500/ \#$  small squares between 1 R-R interval (ie.  $1500/6$  small squares = 250 )
  - Method 3 -  $300 / \#$  large squares between 1 R-R interval (ie.  $300/1.2$  large squares = 250)
  - Method 4 - Calculate # R-R intervals in six seconds (30 large boxes) and multiply by 10. (ie.  $25 \times 10 = 250$ ). – **best if the heart rate is irregular**
  - Method 5 – Count the number of large boxes between the R-R interval. (1 box = 300, 2 boxes = 150, 3 boxes = 100 , 4 boxes = 75, 5 boxes = 60, 6 boxes = 50, 7 boxes = 43, 8 boxes = 38 9 boxes = 33..) (ie. HR is just longer than one box ( $>300$  bpm) and much shorter than two boxes ( $<<150$ )).  
*Using this, determine whether the heart rate is slow, regular fast. In this case, 250 is tachycardic for this infant.*

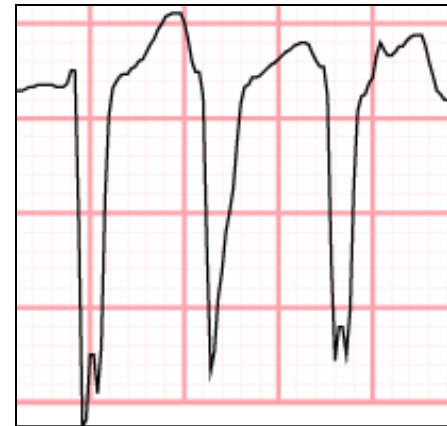
# Case I Term infant: Basic interpretation

## Rhythm

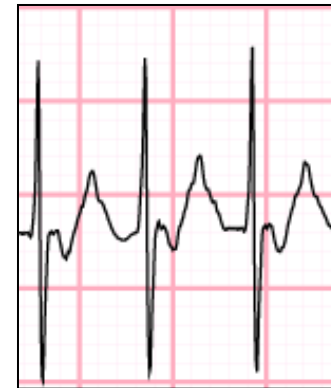- In this patient who is tachycardic, what is the rhythm?
  - We will try to break this down into 4 questions.
- **Question 1 of 4: Is the rhythm regular? – Yes.**
- **Question 2 of 4: Is the tachycardia ventricular in origin, or supraventricular in origin?**
  - This is best answered by looking at the QRS complex.
  - If the QRS is narrow (<0.09 ms, or 2 small boxes), it is a supraventricular tachycardia.
    - supraventricular tachycardias include sinus tachycardia, Atrioventricular reentrant tachycardia (AVRT), AV nodal reentrant tachycardia (AVNRT), atrial flutter, junctional rhythms.
  - If the QRS is wide (> 0.08 ms, or 2 small boxes), one should assume ventricular origin. (It could be atrial however in the case of aberrant conduction).
    - Ventricular tachycardias are best characterized as monomorphic or polymorphic.

-----

Diversion: Generally, we are more worried about ventricular tachycardias as compared with supraventricular tachycardias. We are extremely worried about polymorphic ventricular tachycardias (ie. torsades) because of their tendency to degenerate into ventricular fibrillation and asystole. Ventricular tachycardias are managed more aggressively because of their potential for hemodynamic instability.



wide complex QRS



Our patient with narrow complex QRS

# Case I

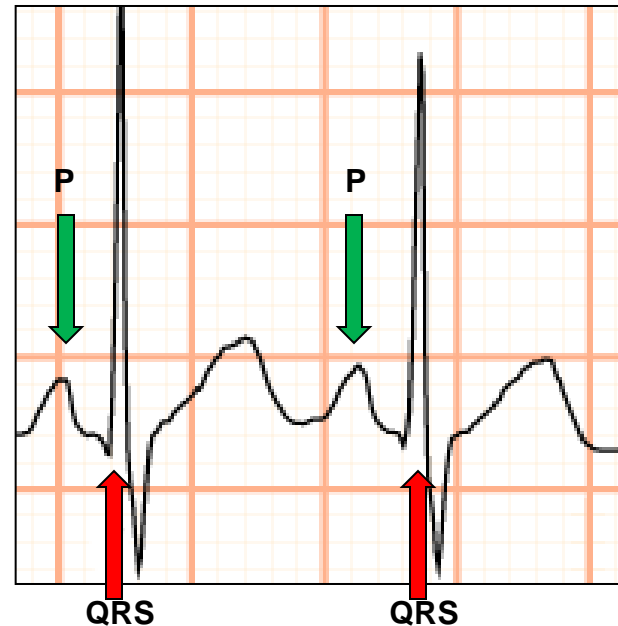
## Term infant:

- Question 3 of 4: Is there a 1-to-1 relationship between the p wave and the QRS complex?
  - If not, (ie. If p to QRS relationship is 2:1, 3:1, or 4:1), consider atrial flutter, particularly if one sees “saw-tooth waves.”
  - If so, most commonly consider sinus tachycardia, atrioventricular reciprocating tachycardia (AVRT), Atrioventricular nodal reciprocating tachycardia (AVNRT), or Atrial ectopic tachycardia. (AET)

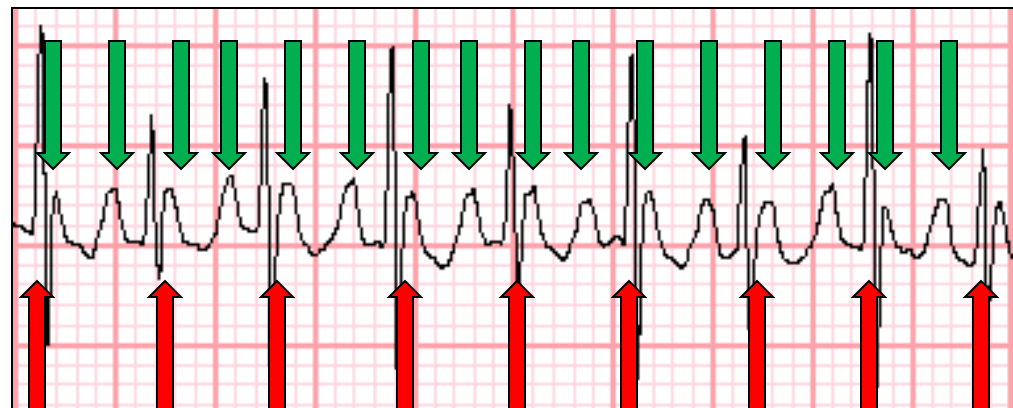
---

(Diversion: it is important to distinguish atrial flutter from other types of supraventricular arrhythmias. It is one of the more common arrhythmias encountered that are refractory to adenosine, and require either pacing or synchronized cardioversion for restoration of sinus rhythm.)

---



Normal ECG



2:1 atrial flutter

# Case 1 term infant:

Question 4 of 4: How can sinus tachycardia be differentiated from other 1-to-1 tachycardias (ie. reentrant tachycardias such as AVRT or AVNRT, or automaticity tachycardias such as AET?)

Sinus Tachycardia	Reentrant Tachycardia (AVRT, AVNRT)	Atrial Ectopic Tachycardia (AET, EAT)
<ul style="list-style-type: none"><li>Conduction Pathway<ul style="list-style-type: none"><li>Sinus node → atrium → AV node → bundle of His → Purkinje fibers → ventricle (reset)... Sinus node → atrium → AV node → bundle of His → Purkinje fibers → ventricle (reset)...</li></ul></li><li>Mechanism<ul style="list-style-type: none"><li>Increased sympathetic drive increases heart rate (fever, hypovolemia, sepsis, anxiety, hyperthyroidism, meds, etc..)</li></ul></li><li>Heart rate<ul style="list-style-type: none"><li>&lt; 220 bpm in infants and &lt;180 bpm in children</li></ul></li><li>ECG<ul style="list-style-type: none"><li>P wave followed by QRS with upright p wave in I and avF.</li></ul></li><li>History (or telemetry)<ul style="list-style-type: none"><li>Will take time to warm up and warm down</li><li>During tachycardia heart rate may vary significantly.</li></ul></li></ul>	<ul style="list-style-type: none"><li>Conduction Pathway (AVRT)<ul style="list-style-type: none"><li>atrium → AV node → bundle of His → Purkinje fibers → ventricle → accessory pathway → atrium → AV node → bundle of His → Purkinje fibers → ventricle → accessory pathway → atrium (etc..)</li></ul></li><li>Mechanism<ul style="list-style-type: none"><li>Reentrant circuit allows normally conducted ventricular impulses to stimulate the atria via accessory pathways.</li></ul></li><li>Heart rate<ul style="list-style-type: none"><li>&gt;220 bpm in infants</li><li>&gt; 180 bpm in children</li></ul></li><li>ECG<ul style="list-style-type: none"><li>P wave occurs shortly after, during, or sometimes just before QRS.</li></ul></li><li>History<ul style="list-style-type: none"><li>Starts suddenly and stops suddenly (paroxysmal)</li><li>During tachycardia very little rate variability.</li></ul></li></ul>	<ul style="list-style-type: none"><li>Conduction Pathway<ul style="list-style-type: none"><li>atrium (with increased automaticity) → AV node → bundle of His → Purkinje fibers → ventricle (reset).. atria (with increased automaticity) → AV node → bundle of His → Purkinje fibers → ventricle (reset)..</li></ul></li><li>Mechanism<ul style="list-style-type: none"><li>Nonsinus atrial foci serve as the pacemaker for the heart at an inappropriately high rate. These foci are responsive to sympathetic and parasympathetic stimuli.</li></ul></li><li>Heart rate<ul style="list-style-type: none"><li>150-300 bpm (often &gt;200)</li><li>The heart rate is <u>inappropriately high</u> for activity level</li></ul></li><li>ECG<ul style="list-style-type: none"><li>Just like sinus rhythm.</li></ul></li><li>History<ul style="list-style-type: none"><li><u>HR inappropriately high for activity level</u></li><li>Will take time to warm up and warm down</li><li>During tachycardia heart rate may vary significantly.</li></ul></li></ul>

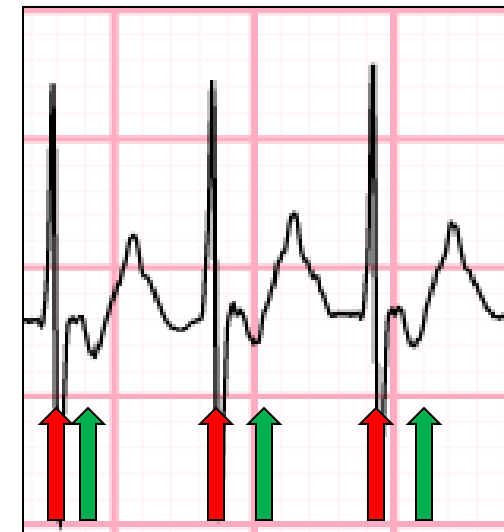
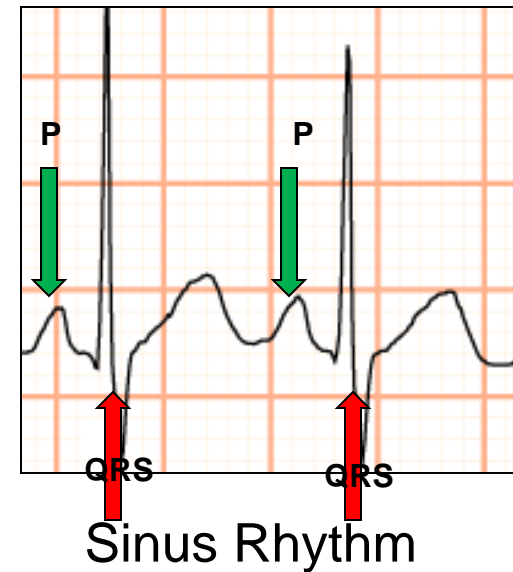
# Case I term infant

## Sinus Tachycardia

- Conduction Pathway
- Heart rate
  - Less than 220 bpm in infants and less than 180 bpm in children
- ECG
  - P wave followed by QRS with upright p wave in I and avF.
- History (or telemetry)
  - Will take time to warm up and warm down
  - During tachycardia heart rate may vary significantly.

## Reentrant Tachycardia (AVRT, AVNRT)

- Conduction Pathway (AVRT)
- Heart rate
  - Greater than 220 bpm in infants
  - Greater than 180 bpm in children
- ECG
  - P wave occurs shortly after, during, or sometimes just before QRS.
- History
  - Starts suddenly and stops suddenly (paroxysmal)
  - During tachycardia very little rate variability.

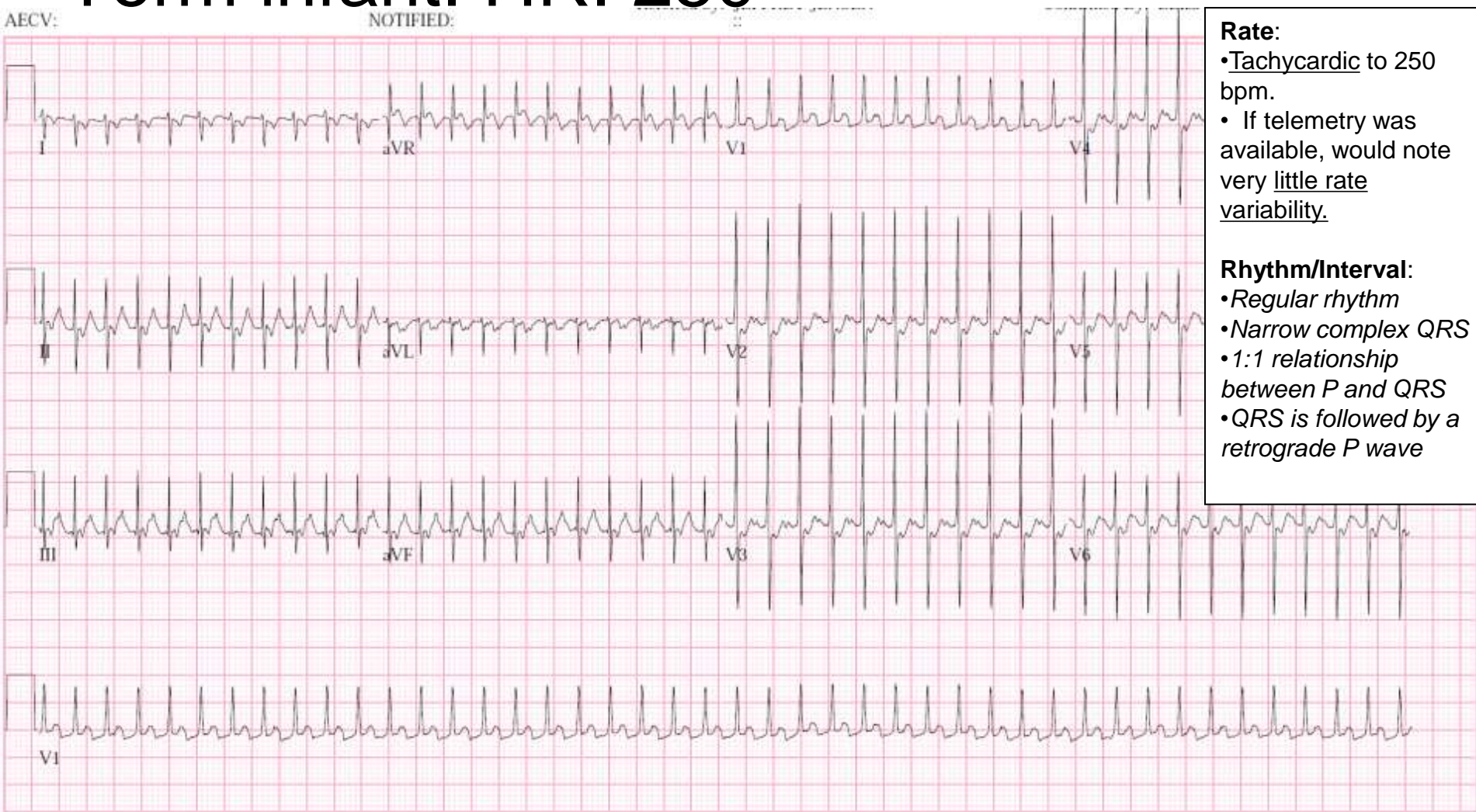


Our patient with retrograde p waves in 1:1 relationship (QRS is followed by p waves). Notice p waves are upside-down



# Case I

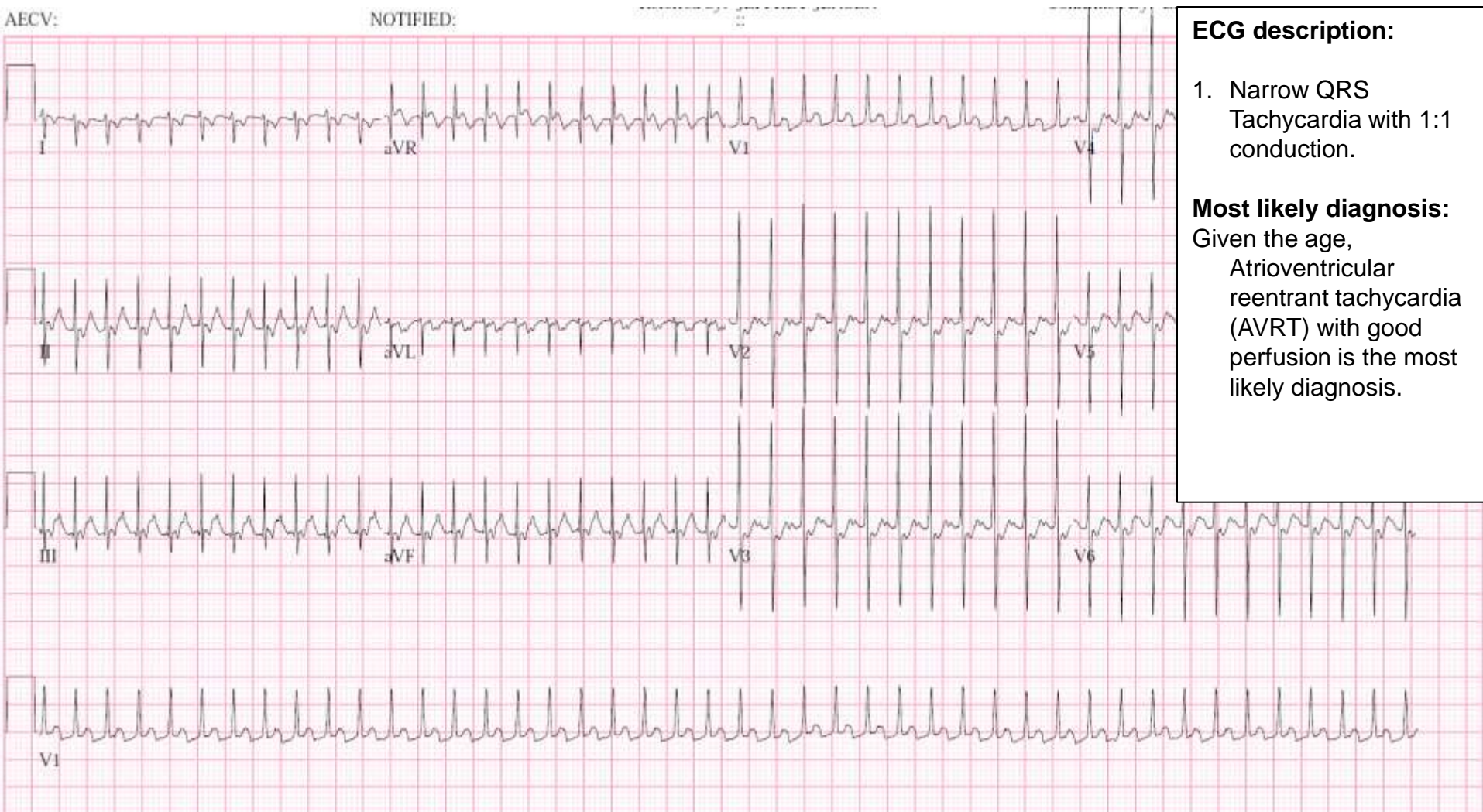
## Term infant: HR: 250



- Rate:**
- Tachycardic to 250 bpm.
  - If telemetry was available, would note very little rate variability.
- Rhythm/Interval:**
- *Regular rhythm*
  - *Narrow complex QRS*
  - *1:1 relationship between P and QRS*
  - *QRS is followed by a retrograde P wave*

# Case I

Term infant: HR: 250





# Case I

Term infant: HR 250

Now this clinically stable patient has been diagnosed with atrioventricular reentrant tachycardia (AVRT), what do you want to do?

# Case I

## Term Infant- Diagnosed with AVRT

### Treatment of stable AVRT.

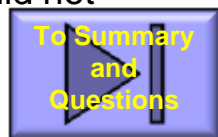
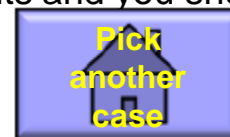- Vagal maneuvers
  - Ice to face for as long as you can hold your breath. (or 10 seconds)
    - Elicits diving reflex.
  - Older kids, blow through a straw, stand on your head, etc..
  
- Chemically break the tachycardia.
  - What do you need?
    - IV placement
    - Defibrillator nearby
      - This is because you don't know what the underlying rhythm is.
    - Running ECG strip (What are you looking for in the ECG?)
      - With an adequate dose of adenosine, AVRT or AVNRT circuit should break tachycardia, but sometimes patients may go right back into tachycardia.
      - Adenosine can be diagnostic if atrial flutter waves at ~400-600 bpm are seen behind the adenosine-induced AV block.
  
  - What is your dosing for Adenosine?
    - Adenosine 0.1 mg/kg IV rapid bolus. (double dose would be 0.2 mg/kg IV)
    - Things to watch? Adenosine may cause bronchospasm. Anticipate this in someone with asthma history

# Case I- Term Infant- Diagnosed with AVRT

## Treatment of stable AVRT.

Argh. Adenosine breaks the tachycardia, then comes back. What can you do?

- Add an antiarrhythmic (Should consult a cardiologist and pharmacy at home institution.. doses written as used at our institution.)
  - Beta blocker (Class II)
    - Esmolol- Class II
      - Load 0.5 mg/kg IV rapid bolus
      - Follow with 50-200 ug/kg/min - micromedex says average dose for response is closer to ~400 ug/kg/min.
      - (Again, with higher dose, remember beta antagonists may cause bronchospasm)
    - Propranolol IV
  - Procainamide – Class Ia
    - 7-15 mg/kg IV load over 15-30 minutes (This **load** is VERY Important as without load likely will not achieve high enough steady state to break tachycardia. )
    - Infusion 20-60 ug/kg/min
    - (REMEMBER THAT PROCAINAMIDE CAN BE PROARRHYTHMIC)
  - Amiodarone – Class III. # 1 on PALS
    - 5 mg/kg IV load over 30 minutes (VERY Important to load amiodarone **slowly** since rapid infusion can depress myocardial function.)
    - Infusion 5-10 mg/kg over 24 hours.
    - Procainamide and amiodarone should not be administered together as pharmacokinetics multiply toxicity.
- Bonus: Which drug commonly used in adult AVRT is contraindicated in infants and you should not use!
  - **Verapamil is contraindicated in children less than 12 months.**

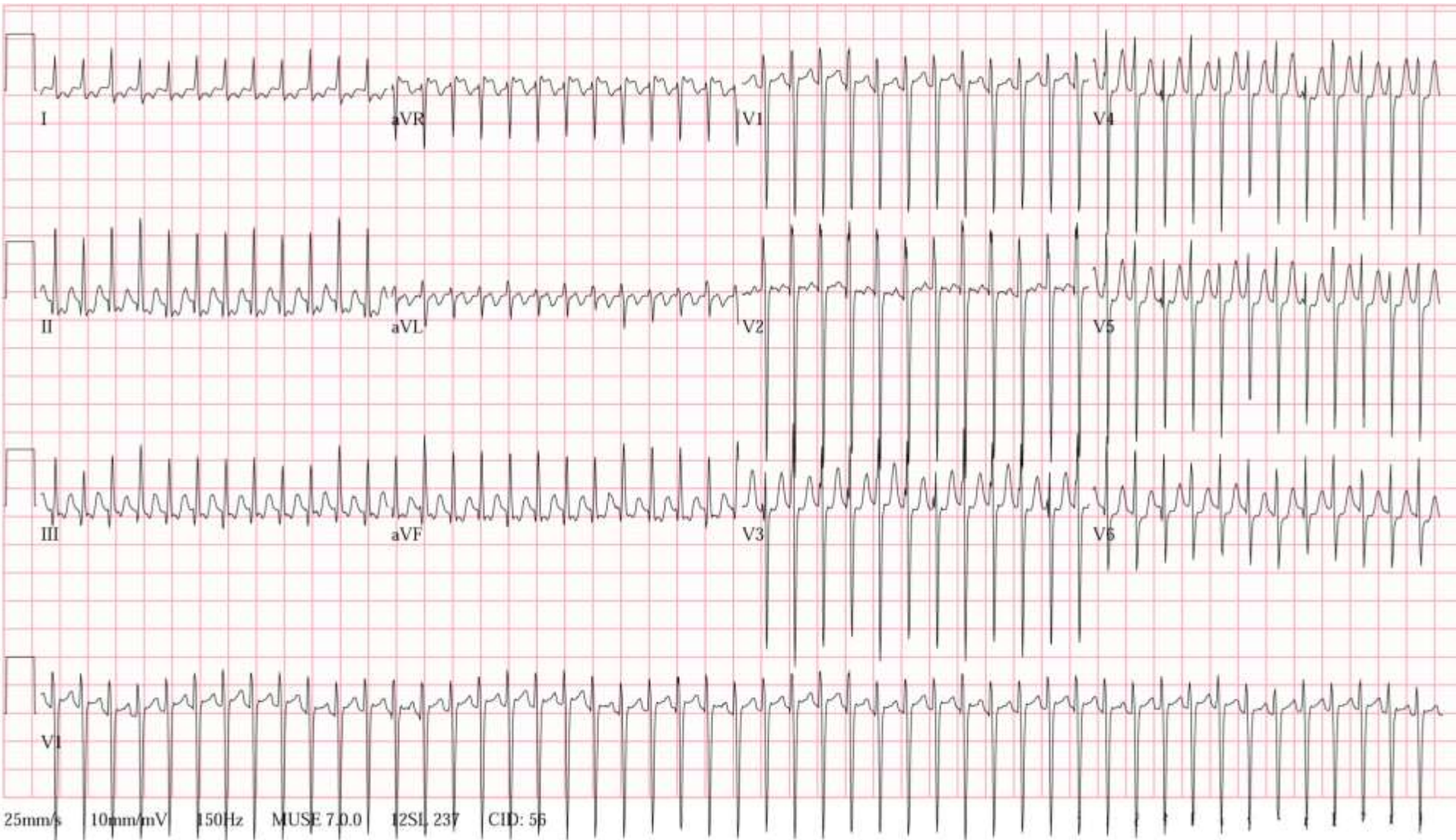


# Case II

## Term Infant- HLHS

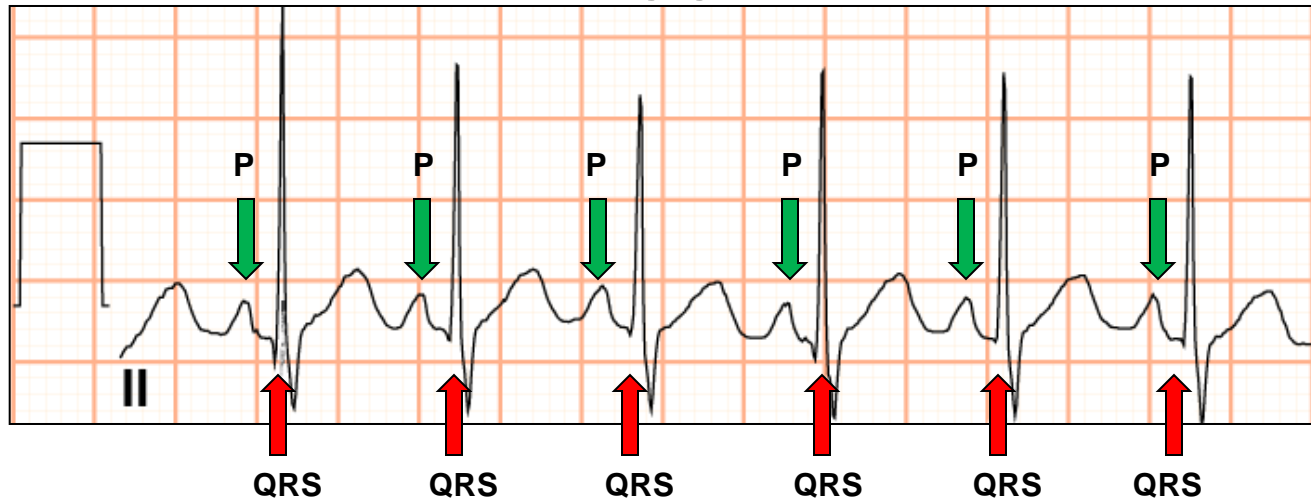
- Two week old infant with hypoplastic left heart syndrome s/p Norwood/Sano palliation sailed through the PICU and arrived on the floor on POD # 7. The surgery fellow gives you a call asking you to evaluate this patient's rhythm on the floor.
- His heart rate is 300 bpm, appears comfortably tachypneic at 70 breaths per minute, with oxygen saturations at 75% on 1 Liter nasal cannula. Perfusion is 3 seconds.
- What should you do?

# Case II Term Infant- HLHS

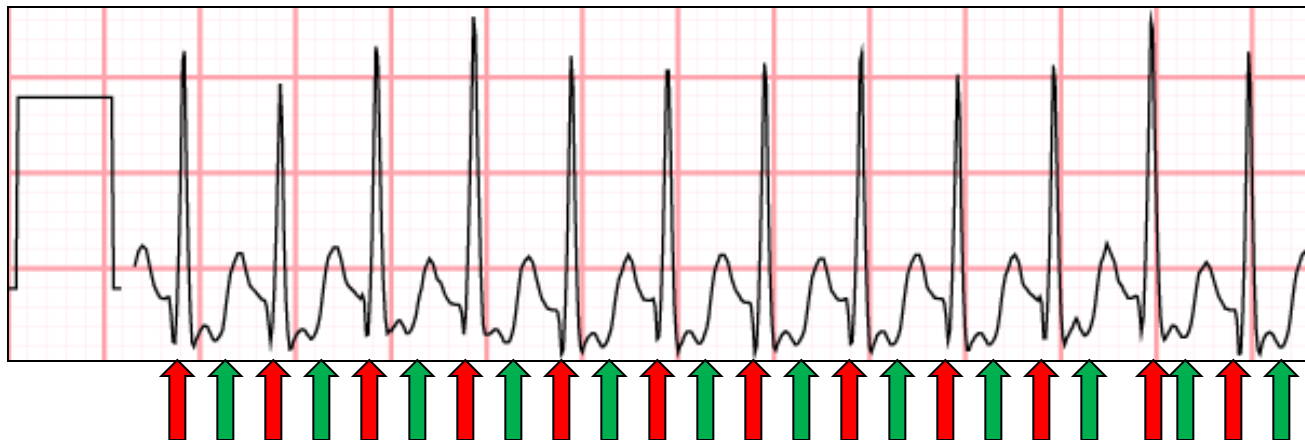


# Case II Term infant - HLHS

## Normal ECG



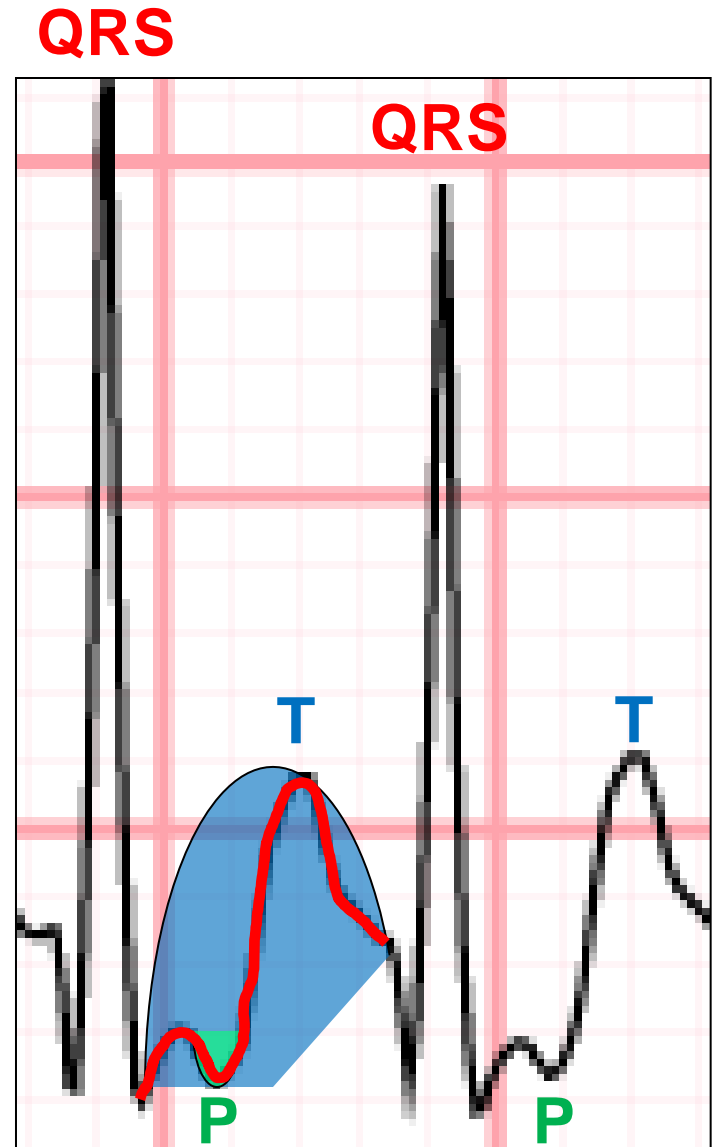
## Patient's ECG



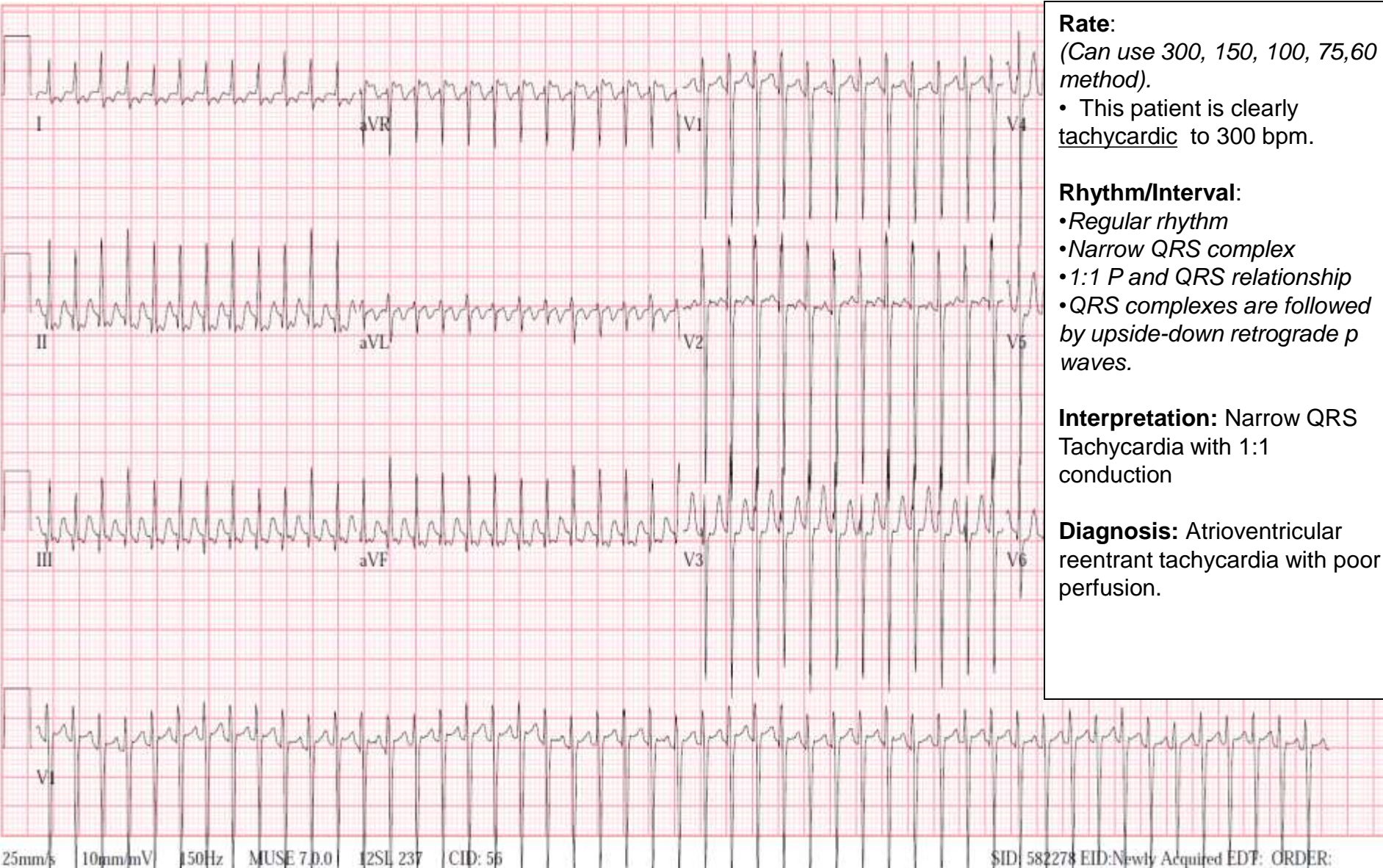


# Case II Term infant - HLHS

- A closeup of the ECG.
- **QRS complexes** and **T waves** are easily identified.
- Where is the P wave?
  - Upside-down **P waves** are buried in the T wave.
  - So the p wave is not the initial small upslope, but is the second downslope
  - Another way to think of this
    - imagine a broad **positive T wave** one would see with a normal ECG.
    - Superimpose a **negative p wave**
    - The summation of the **positive T wave** and **the negative p wave** results in the **curve** one would see on an ECG.



# Case II Term infant -HLHS



**Rate:**  
(Can use 300, 150, 100, 75, 60 method).  
• This patient is clearly tachycardic to 300 bpm.

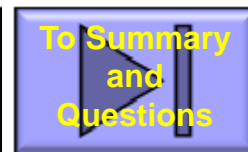
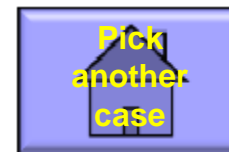**Rhythm/Interval:**  
• *Regular rhythm*  
• *Narrow QRS complex*  
• *1:1 P and QRS relationship*  
• *QRS complexes are followed by upside-down retrograde p waves.*

**Interpretation:** Narrow QRS Tachycardia with 1:1 conduction

**Diagnosis:** Atrioventricular reentrant tachycardia with poor perfusion.

# Case II – Term Infant HLHS

- Infant with AVRT with poor perfusion...
  - If IV available, give adenosine (0.1 mcg/kg), if not successful may double dose.
  - Cardioversion
    - Sandwich technique (more critical in Aflutter-Afib situation)
    - **PRESS THE SYNC BUTTON. ALWAYS**
      - Remember that shocking on the T wave is used to purposely induce vfib in the EP lab. We try to avoid this when cardioverting patients.
    - Voltage?
      - AVRT and atrial flutter will generally require less voltage than atrial fibrillation or ventricular tachycardias
      - Many books and attendings will recommend starting with 0.5 Joule/kg especially with the biphasic cardioversion devices. If this fails, can double energy.
  - Call Cardiology – like previous case, if above measures are refractory additional medications (ie. esmolol, amiodarone) may be given
- Look at the child to determine therapy. With structurally normal heart and good function and reassuring clinical exam, SVT may be tolerated well in the short-term. If anything is not, beware.

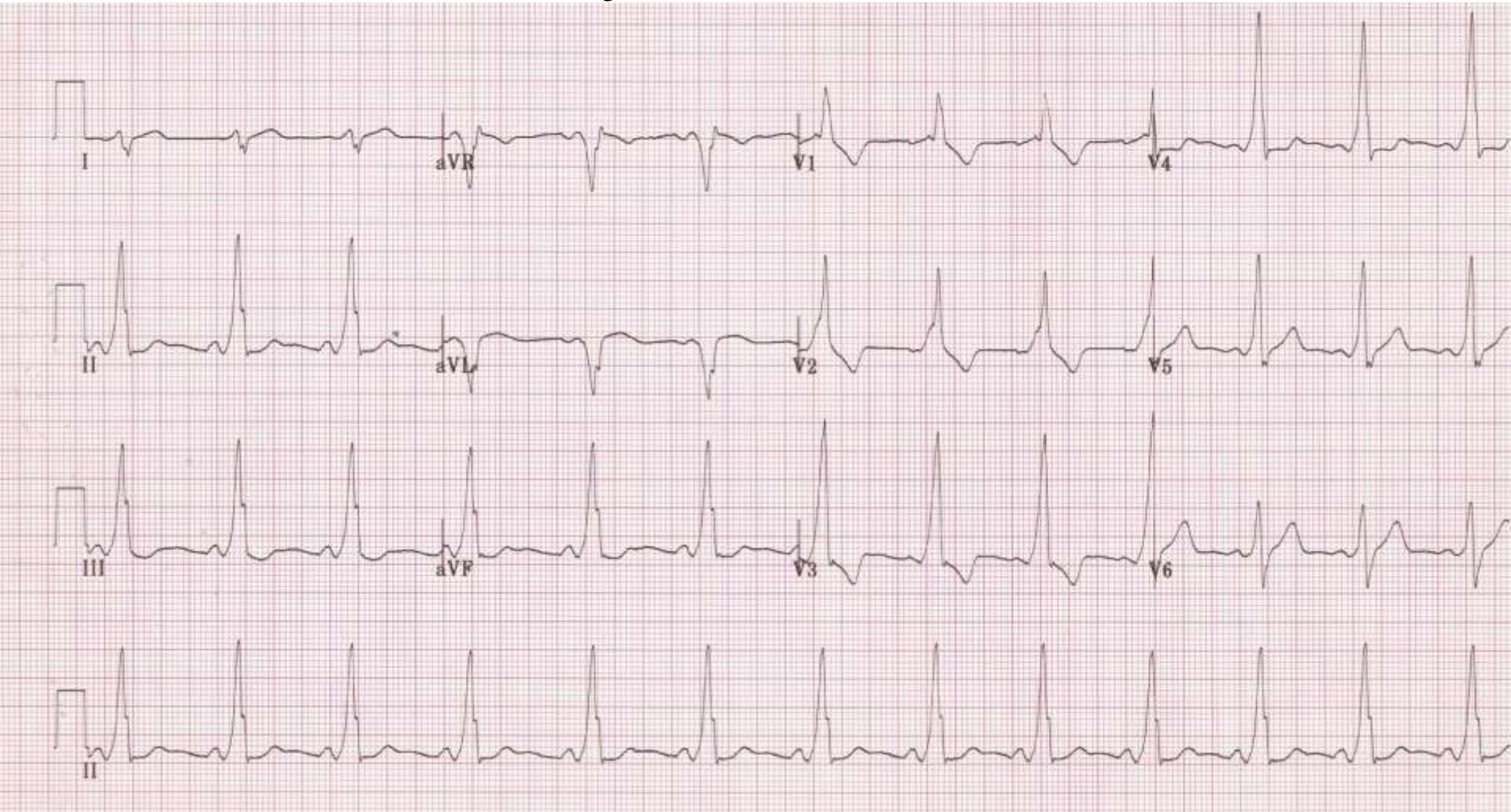


# Case III

- A 10 year old boy with a vague history of “a racing heart beat” was on a whitewater rafting trip when he suddenly slumped over. His dad noticed breathing was shallow, pulses were fast and poor, and was able to administer effective CPR while a bystander called EMS.
- EMS successfully “shocks” the patient at the next stop.
- The patient, now appearing well, presents at your hospital with the ECG strip from the event lost two transfers ago, clinically appearing well.

# Case III

Please Identify this ECG



# Case III

## Please Identify this ECG

Preexcitation (ECG w/delta wave), or Wolf-Parkinson-White (WPW)

The normal QRS is a result of normal sequential depolarization

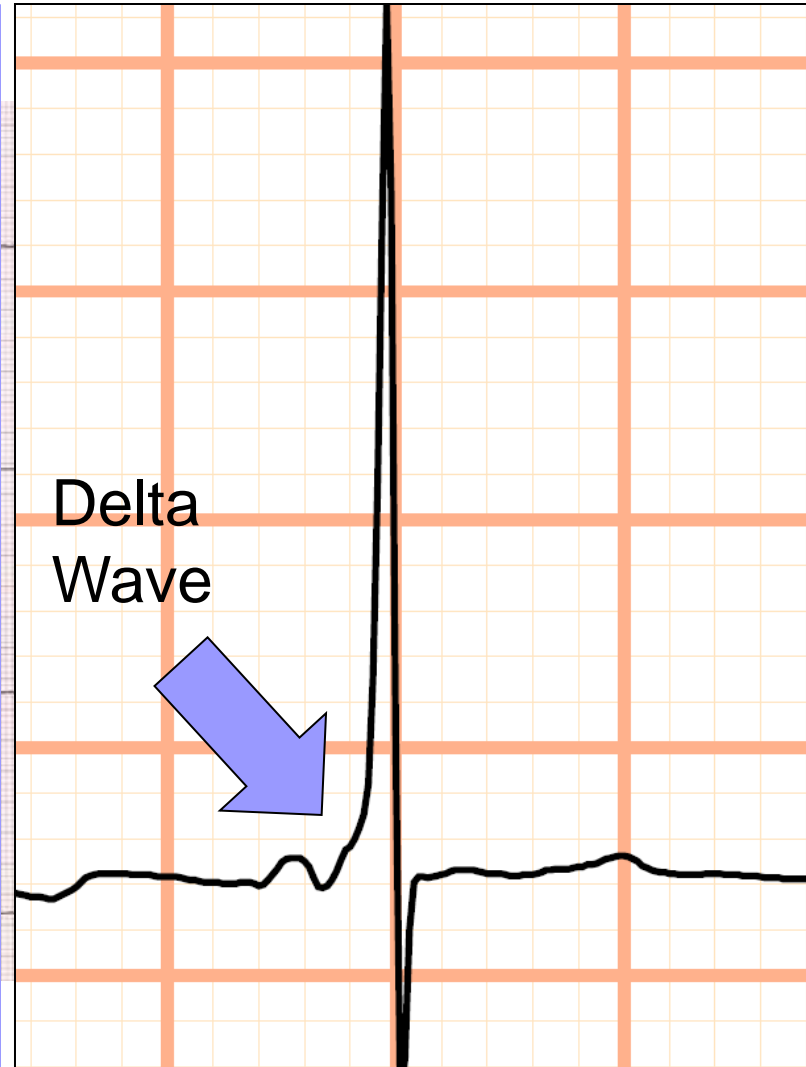
1. SA node
2. Atria
3. AV Node (Slow) – PR interval.
4. Purkinje Fibers
5. Ventricle

With an accessory pathway, sequential depolarization can be shortened.

1. SA node
2. Atria
3. Accessory pathway (Faster)
4. Ventricle

As some of the ventricle has already begun to depolarize prior to the regular impulse through normal conduction, the PR interval is shortened and there is a “delta wave”.

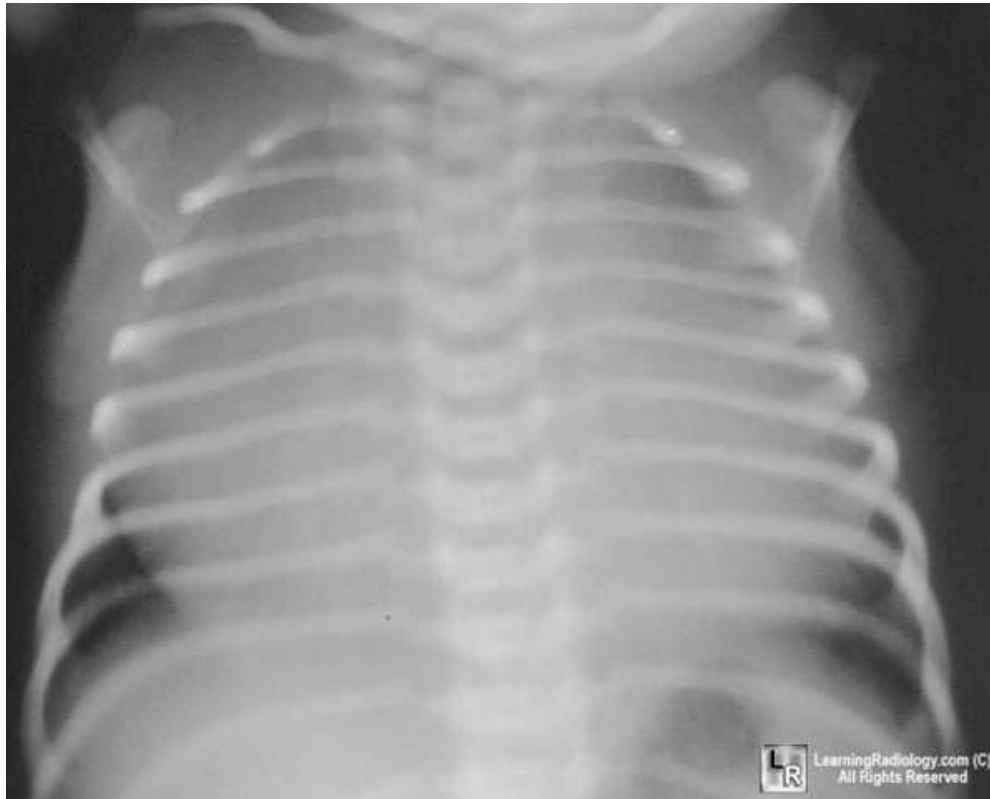Preexcitation (ECG w/ delta wave) is one of the setups for Atrioventricular reentrant tachycardia, as well as sudden death (more on that later)



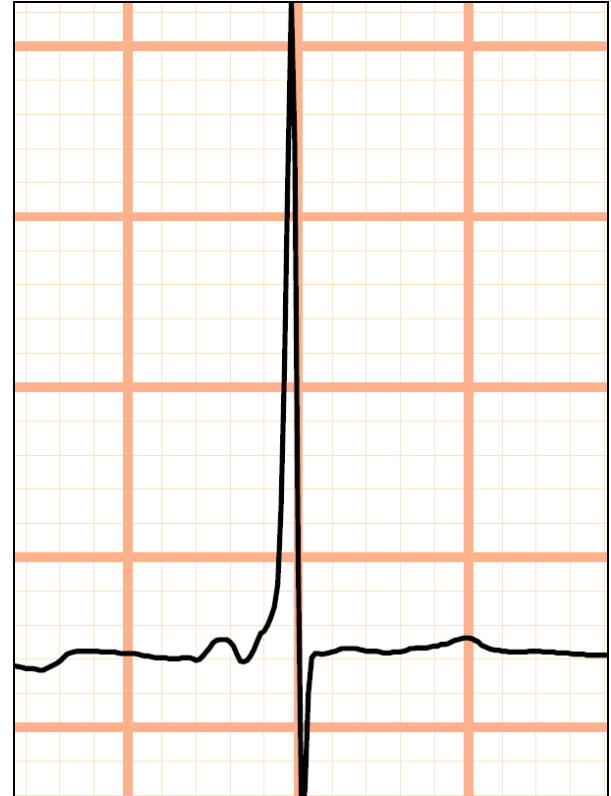
# Case III

## Term Infant

*Diversion.....what if the infant had*



&

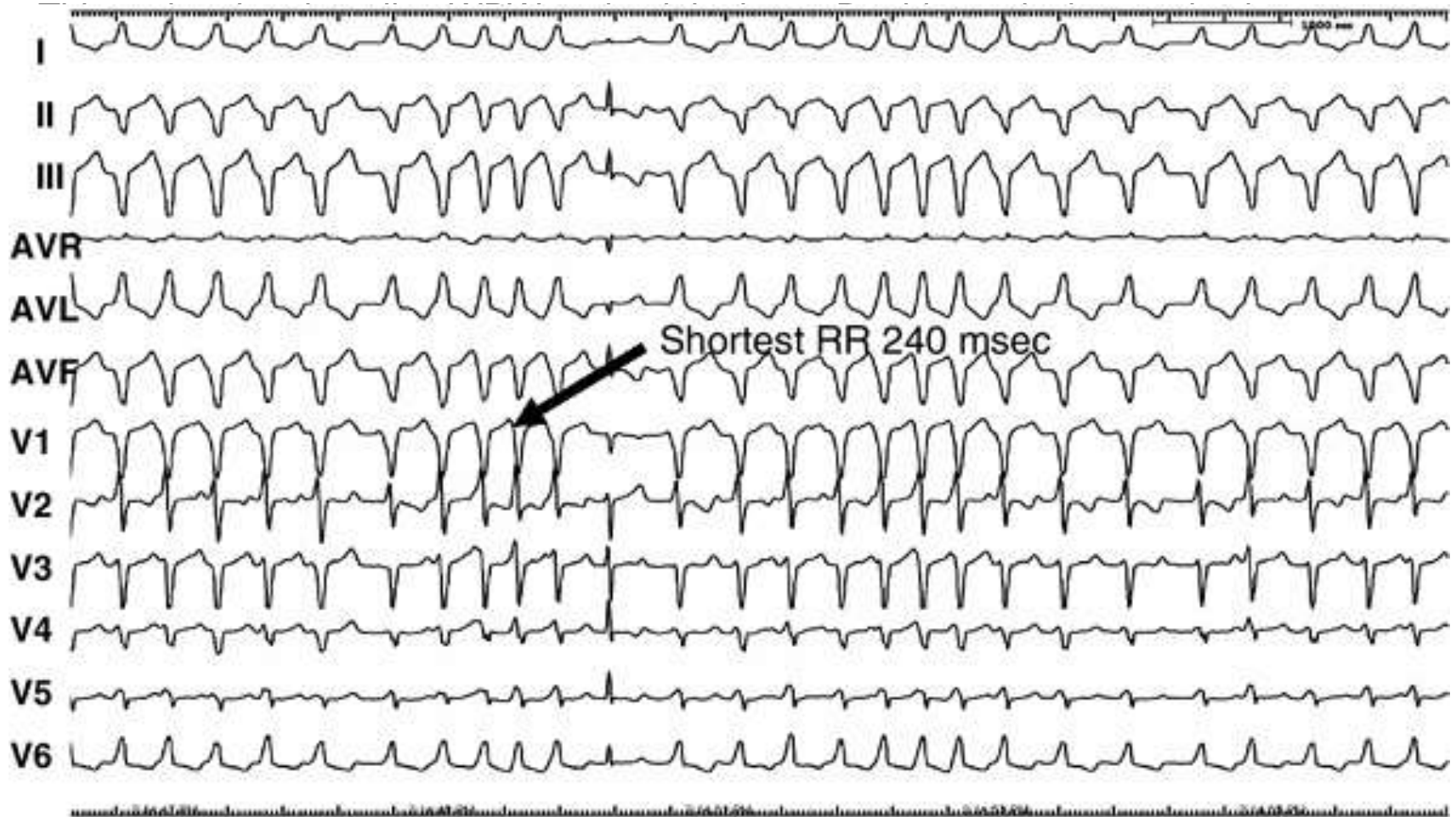


?

Wall-to-wall heart with WPW (Delta wave) is classic for Ebstein's anomaly

# Case III

The ECG one may have seen during the rafting event.



Note irregular rhythm and wide QRS complexes.  
This should make anyone nervous.



# Case III

## Answer: Atrial Fibrillation with rapid ventricular response

- This unusual ECG demonstrates a patient who has Wolf-Parkinson-White (preexcitation) who is able to rapidly conduct across this accessory pathway.

- This results in a dangerous situation if this patient develops atrial fibrillation. If atria is fibrillating at 400-700 beats usually the AV node is able to “filter” this very rapid response, and ventricular activation is limited.

- However, if there is an accessory pathway that is efficient and able to conduct rapid atrial impulses, the ventricle will respond just as fast. This is why atrial fibrillation with WPW with an efficient accessory pathway (that can conduct impulses quickly) can result in ventricular fibrillation and loss of cardiac output.

- Thus with an efficient accessory pathway, atrial fibrillation begets ventricular fibrillation, and can result in sudden death.

---

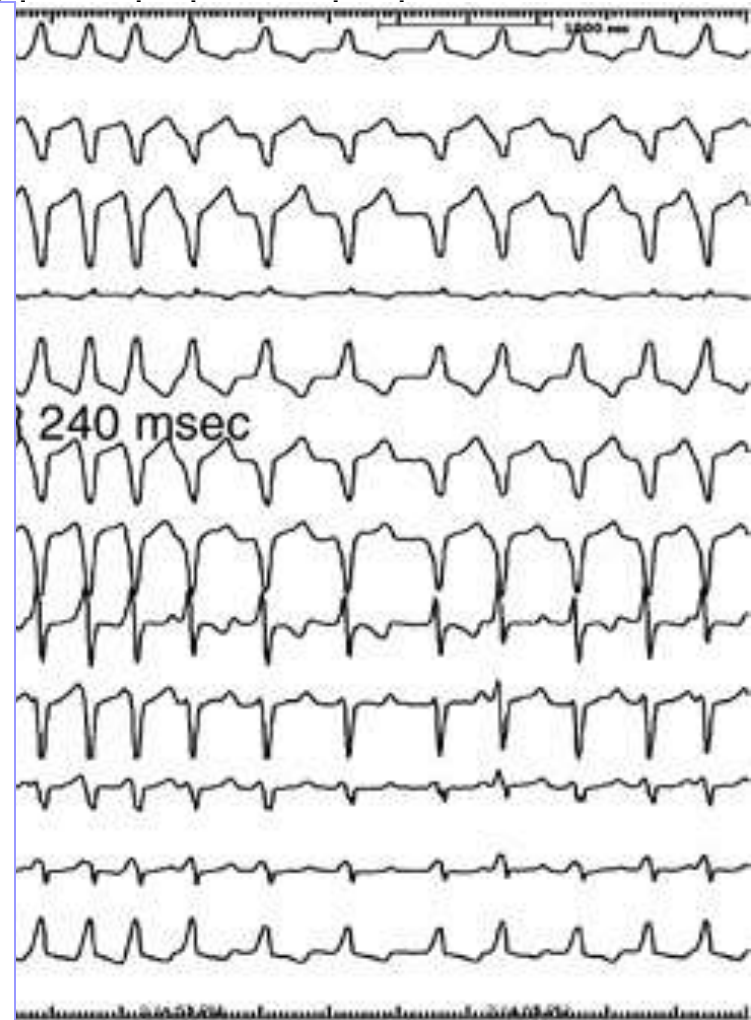
- Atrial fibrillation with rapid ventricular response can occur in children and adults.

- Risk of sudden death with WPW beyond neonatal age is quoted at 0.1-0.2% a year.

---

- If one sees an ECG with wide QRS complex with an irregular rhythm, this is pathognomonic for **atrial fibrillation with rapid ventricular response**, not typical ventricular tachycardia.

- **The rhythm shown is an indication for cardioversion 2-4 J/kg. Sync if possible.**



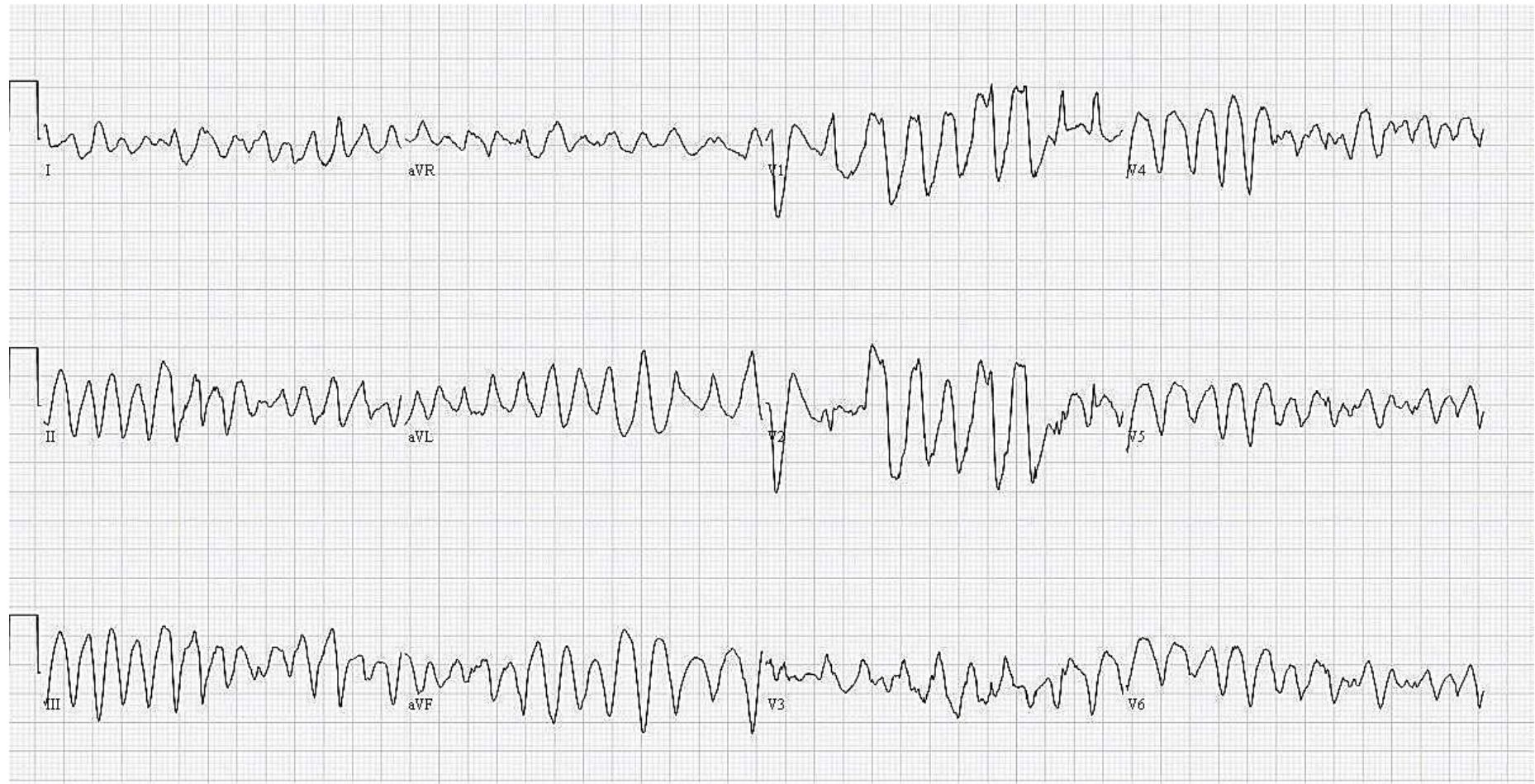Pick  
another  
case

To Summary  
and  
Questions

# Case IV - child

- A previously 10 year old boy is found down to be unresponsive in a swimming pool. The patient is unconscious, manually bagged and receiving compressions as you see him coming through the ER doors.
- He has an extremely thready pulse, saturations in the 80's, and a blood pressure of 40/palp.
- An ECG is obtained.

# Case IV - child



# Case IV - child

- Wide complex QRS with variable morphology.
- Polymorphic ventricular tachycardia
  - more specifically, Torsades de pointes
- Patients are invariably unconscious as this rhythm does not result in effective perfusion.
- The history for drowning is classic for Long QT syndrome, particularly Long QT1, a potassium mutation that increases the risk for torsades de pointes and sudden cardiac death.

---

## Management Caveat

Note that patients with ventricular tachycardia could be relatively hemodynamically stable (ie. many types of monomorphic tachycardia) and one would follow PALS tachycardia algorithm. Or, patients could be hemodynamically unstable (ie. Torsades, other types of polymorphic Vtach. where one would follow the pulseless arrest protocol. Again, ascertaining one's clinical status is extremely important.

---

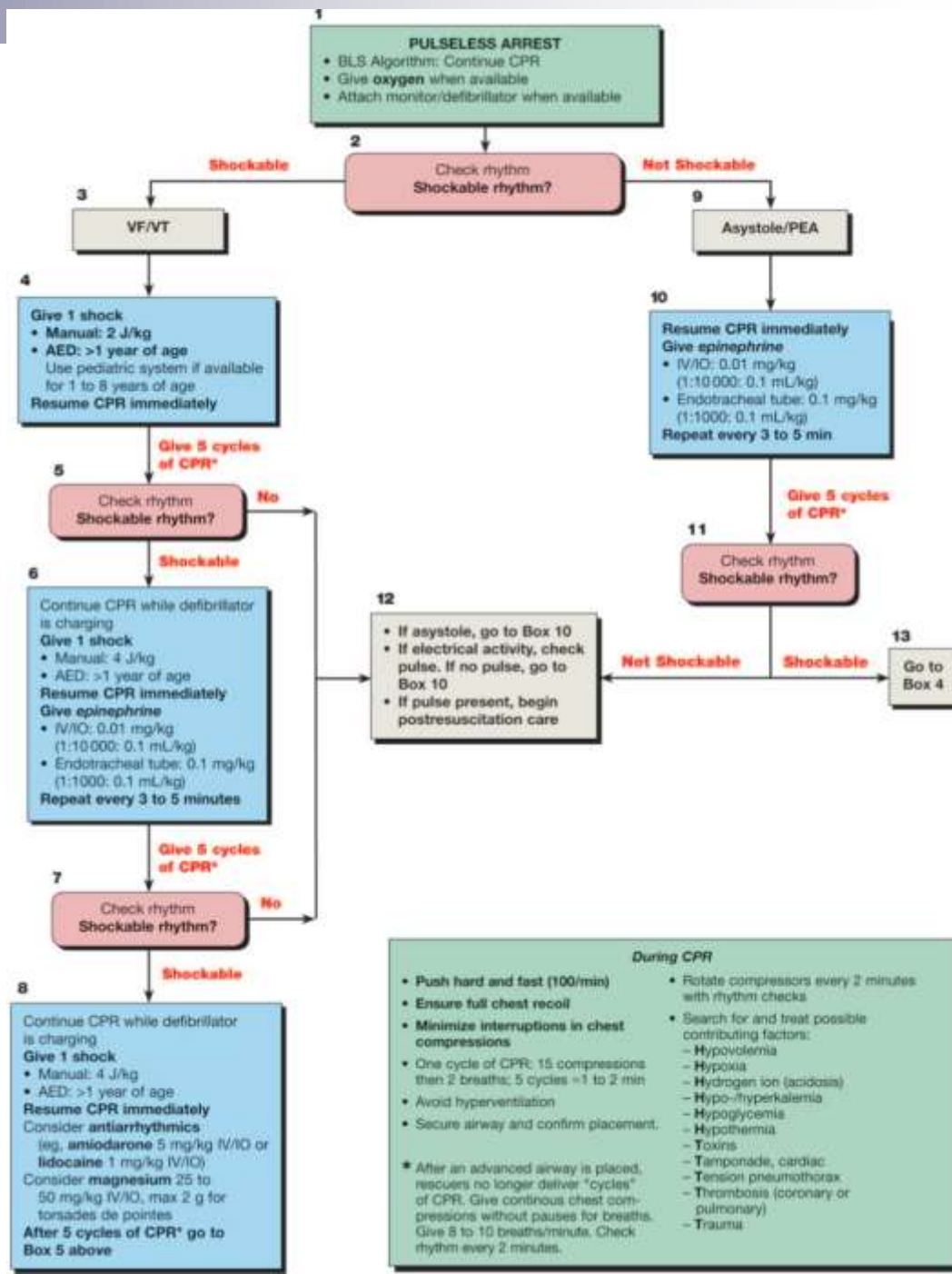
# Case IV - child

Follow pulseless arrest protocol.

- Oxygen
- Effective compressions
- Effective ventilation

Treatment of polymorphic V-tachycardia rhythm includes

- Unsynchronized cardioversion with 2-4 joules/kilogram (do not delay)
- Epinephrine 0.01 mg /kg IV
- Amiodarone 5 mg/kg IV
- Lidocaine 1 mg/kg IV
- Magnesium 25-50 mg/kg IV



Pick another case

To Summary and Questions

# Summary Slide

- Reentrant supraventricular tachycardia can be managed by vagal maneuvers, medications, and cardioversion
- Method of management depends on the patient's acuity as well as success/failure of treatment
- Be able to recognize Preexcitation (WPW) as a substrate for reentrant supraventricular tachycardia as well as a potential risk factor for sudden cardiac death (0.1-0.2% per year).
- Recognize Ventricular tachycardia and basic management for pulseless arrest.

# Post Test Questions

## 1. What is common characteristic for SVT?

- A. It is usually responsive to furosemide.
- B. Heart rate slowly increases and slowly decreases
- C. Calcium Channel blockers are contraindicated for infants < 12 months
- D. Synchronized cardioversion is usually indicated for SVT with good perfusion.
- E. Diving reflex is elicited by sternal rub.

## 2. Wolf Parkinson White Syndrome

- A. Is characterized by an epsilon wave
- B. Usually has a long PR interval
- C. Can result in sudden death
- D. With wall-to-wall heart is classically associated with anomalous left coronary artery to the left pulmonary artery (ALCAPA)
- E. Is a risk factor for atrial flutter.

# Post Test #1 Answer

1. What is common characteristic for SVT?

- A. It is usually responsive to furosemide.
- B. Heart rate slowly increases and slowly decreases
- C. Calcium Channel blockers are contraindicated for infants < 12 months
- D. Synchronized cardioversion is usually indicated for SVT with good perfusion.
- E. Diving reflex is elicited by sternal rub.

Answer:

- C. Calcium Channel blockers are contraindicated for in SVT for infants < 12 months because they can depress cardiac function. This is in contrast to adult management of SVT where calcium channel blockers are readily used.



# Post Test #2 Answer

## 2. Wolf Parkinson White Syndrome

- A. Is characterized by an epsilon wave
- B. Usually has a long PR interval
- C. Can result in sudden death
- D. With wall-to-wall heart is classically associated with anomalous left coronary artery to the left pulmonary artery (ALCAPA)
- E. Is a risk factor for atrial flutter.

Answer: C. Wolf Parkinson White can result in sudden death, particularly in cases where atrial fibrillation is rapidly conducted across the accessory pathway causing ventricular fibrillation. The typical risk for sudden death is usually quoted at 0.1-0.2% a year.

# Pre-Test Question #1

- You are called to the bedside of a patient with a heart rate of 250 bpm who looks comfortable. ECG shows narrow QRS with 1:1 P and QRS relationship. What should you do?
  - A. Bolus 20 cc/kg Normal Saline
  - B. Start Adenosine
  - C. Defibrillate
  - D. Synchronize cardioversion
  - E. Try vagal maneuvers

Answer:

- E. Trying vagal maneuvers is the correct initial management in a stable patient with supraventricular tachycardia. Failure will require additional medical management.

# Pre-Test Question #2

- You are called to the bedside of a patient with a heart rate of 300 bpm who has poor perfusion. ECG shows narrow QRS with 1:1 P and QRS relationship. Of the following, what should you do?
  - A. Obtain a chest x-ray
  - B. Start propranolol.
  - C. Defibrillate
  - D. Synchronize cardioversion
  - E. Tilt-table Test

Answer:

D. Synchronized cardioversion is the correct initial management for supraventricular tachycardia for a patient with poor perfusion of the choices given. Adenosine would also be a reasonable answer if IV access is readily available.

# References

Good ECG examples to find on the web

- <http://www.learntheheart.com/EKGreview.html>
- [www.heartpearls.com](http://www.heartpearls.com)

Good Chest X-rays

<http://www.learningradiology.com/>

Reading for Tachyarrhythmias

- Allen H, Driscoll D, Shaddy R, Feltes T ed. Moss and Adams' Heart Disease in infants, children, and adolescents- 7<sup>th</sup> edition. Philadelphia, 2008. 293-342.
- Walsh E, Saul J, Triedman. Cardiac Arrhythmias in children and young adults with congenital heart disease. Philadelphia, 2007. Chapter 5.

Normal Values

- Behrman R, Kliegman R, Jenson H ed. Nelsons Textbook of Pediatrics 17<sup>th</sup> edition. Philadelphia, 2004. 280.

Pediatric Advanced Life Support Reference

- [http://circ.ahajournals.org/cgi/content/full/112/24\\_suppl/IV-167](http://circ.ahajournals.org/cgi/content/full/112/24_suppl/IV-167)