



Night Float Module Interpretation of Chest Radiographs

National Pediatric Nighttime Curriculum
Written by LaToya S. Barber, MD and
Francine D. Bynum, MD
Childrens Hospital Los Angeles



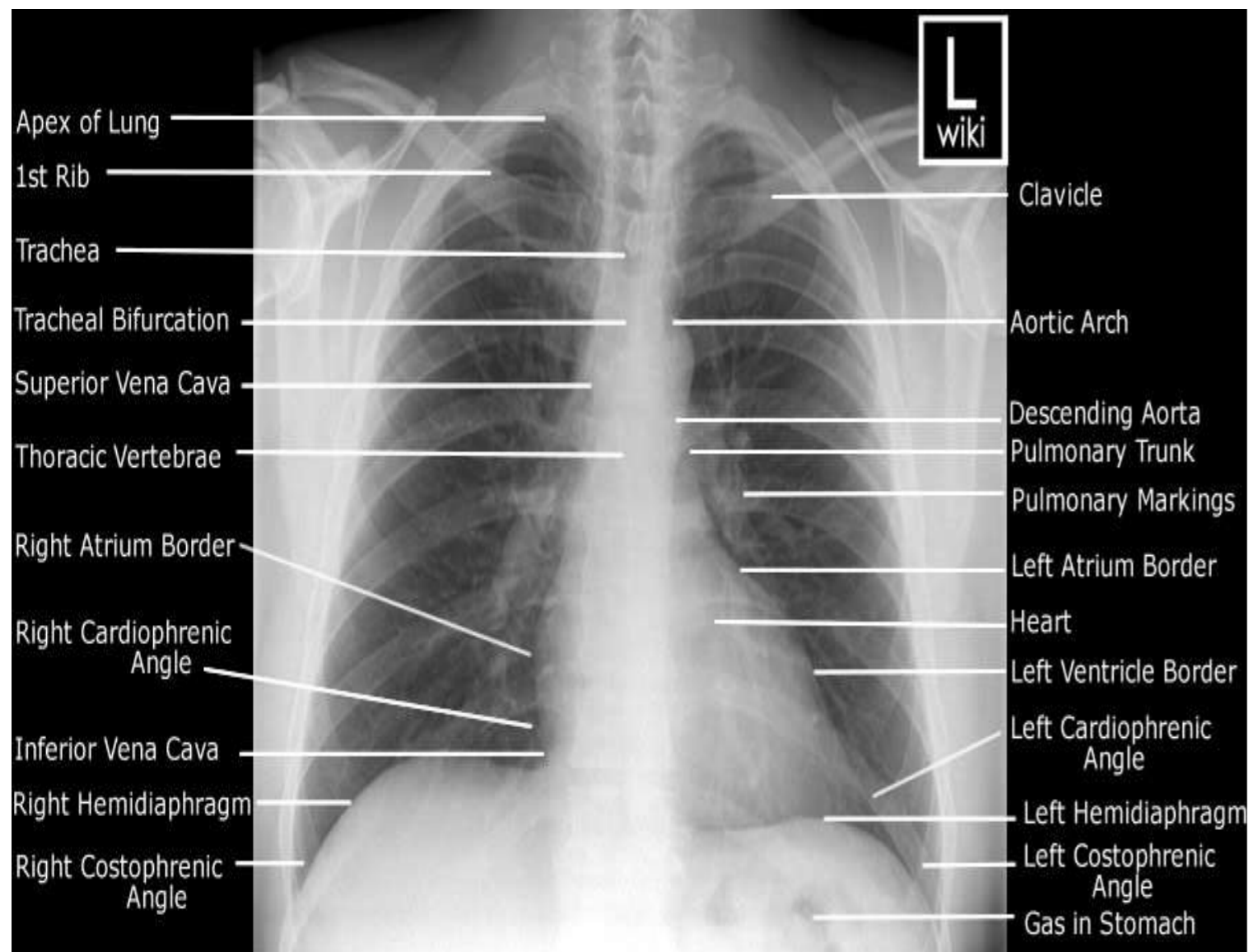
Goals And Objectives

- Develop a comprehensive approach to reading chest x-rays
- Identify the following conditions on chest x-ray
 - pneumonia and its complications
 - pneumothorax
 - atelectasis
- Describe two radiographic features for both pneumonia and pneumothorax

Chest Radiography

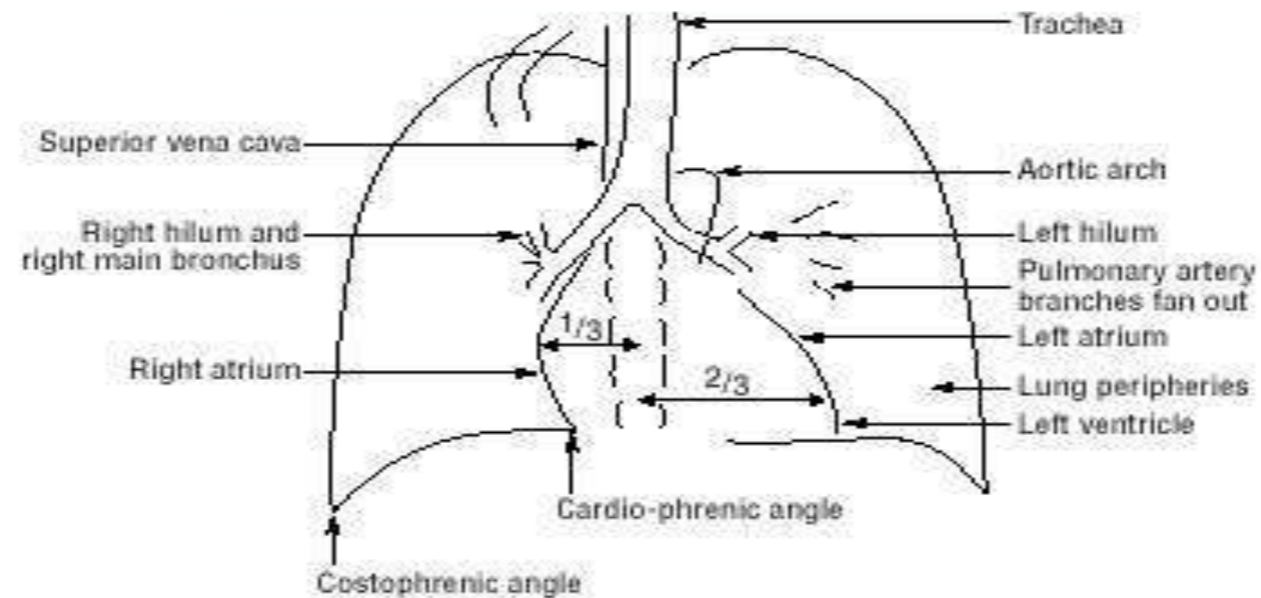
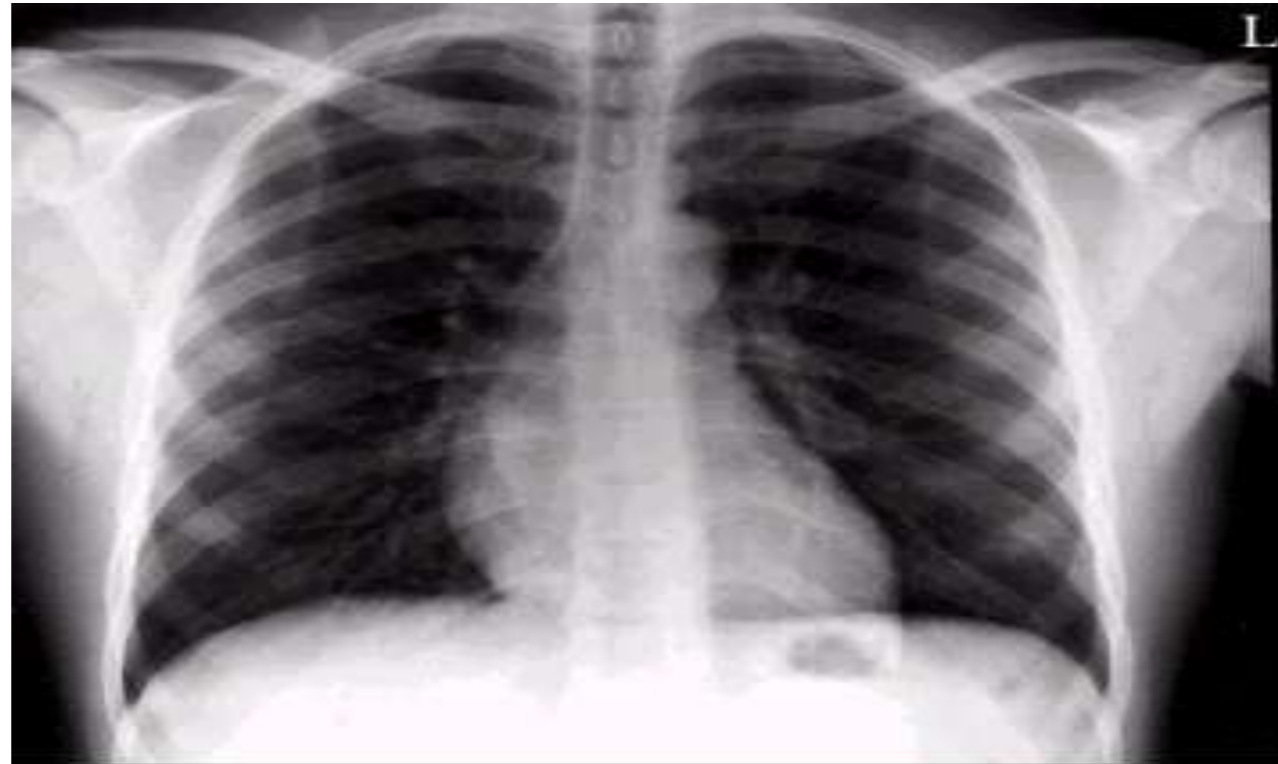
- Proven and useful tool for the evaluation of...
 - Airways, lungs, pleura, and chest wall
 - Heart, pulmonary vessels, and mediastinum
- Most common type is posteroanterior (PA):
 - x-rays enter through the posterior (back) aspect of the chest and exit out of the anterior (front) aspect of the chest)
- Anteroposterior (AP) and lateral films also common

Components of a PA Chest X-Ray

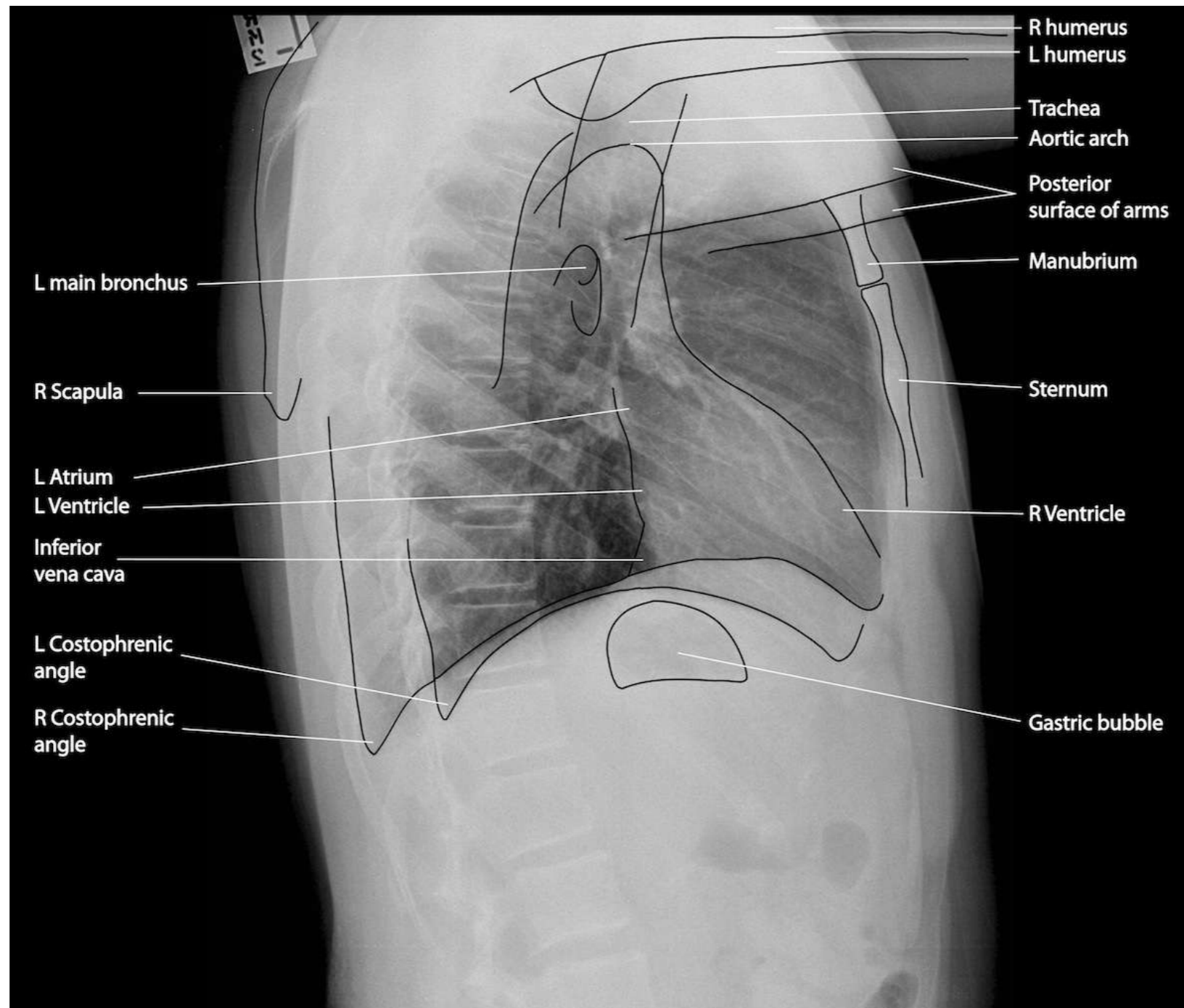


- Inclusive of following structures:
 - Both lung apices
 - Both costophrenic angles
 - Mid-thoracic vertebral bodies, centered on film
 - Left retro-cardiac pulmonary vessels
- Technical considerations:
 - Arms must be elevated to prevent scapula from obscuring lung fields (PA film) and upper arms from obscuring chest (lateral film)

PA Chest X-Ray: Anatomic Correlation



Lateral Chest X-ray: Anatomic Correlation



Approach to Interpretation of Chest X-ray: “Top to Bottom”

■ Airway:

- Evaluate Trachea and thoracic inlet (should be centrally located)

■ Lungs:

- Look at expansion and inspiratory effort (should be able to count 11 ribs)
- Look for opacities, consolidation, fissures, fluid, air bronchograms
- Compare the right and left lung

■ Heart and Large Vessels:

- Evaluate heart size and shape
- Evaluate the location and prominence of vessels

Approach to Interpretation of Chest X-ray: “Top to Bottom”

■ Diaphragm:

- Look at elevation bilaterally
- Evaluate for free air underneath

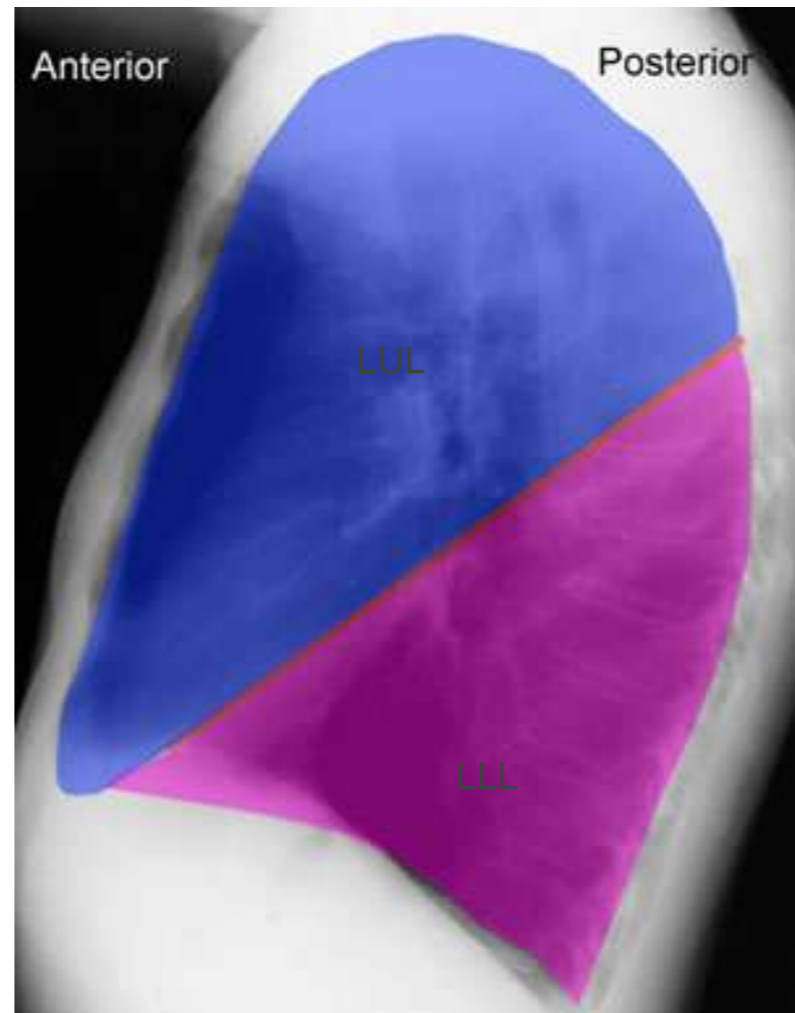
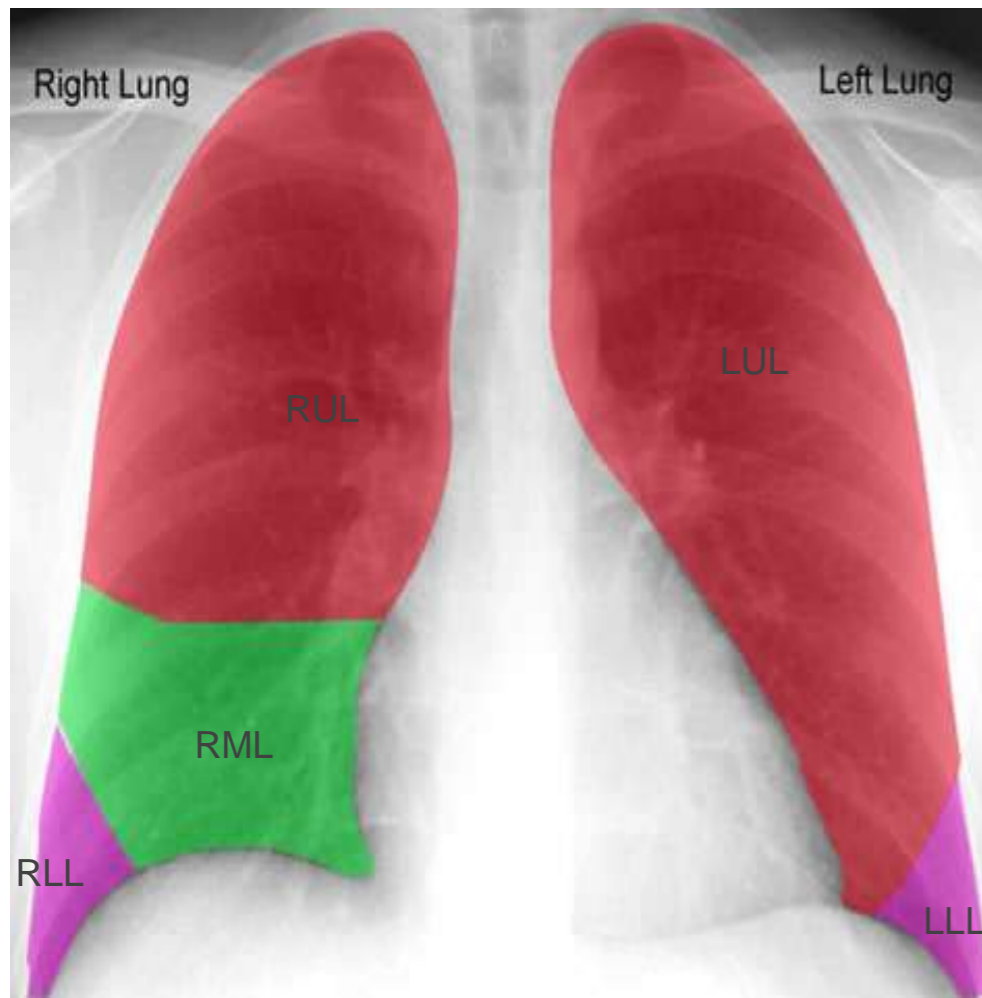
■ Bones:

- Look for fractures and deformities
- Evaluate bone density

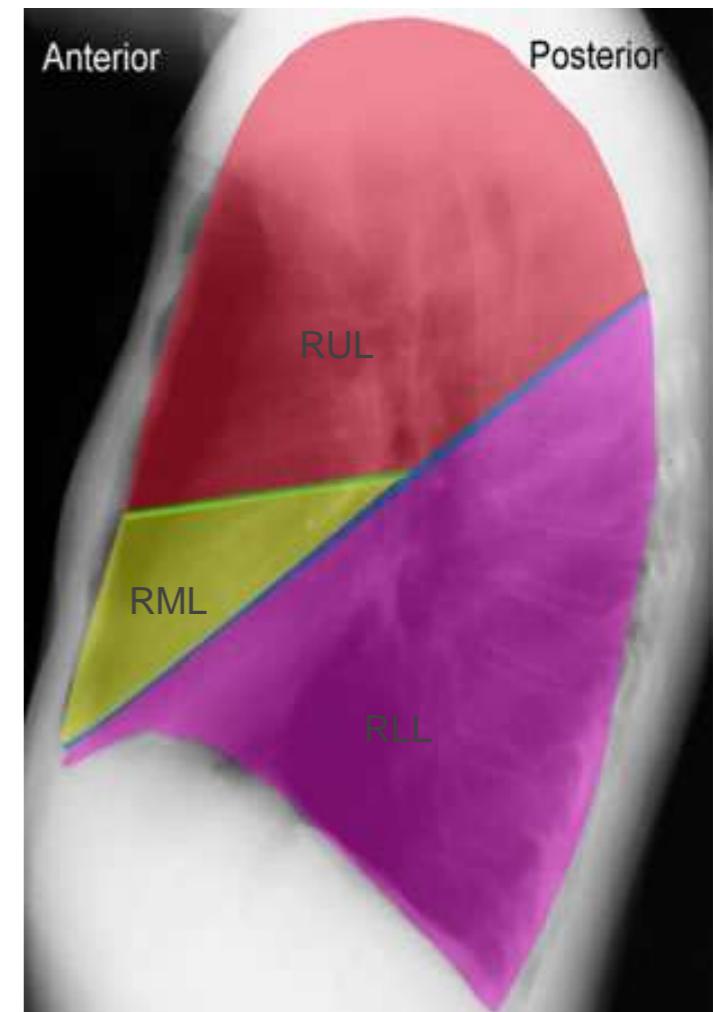
■ Upper Abdomen:

- Look for stomach bubble
- Evaluate liver size

Lobes and Fissures



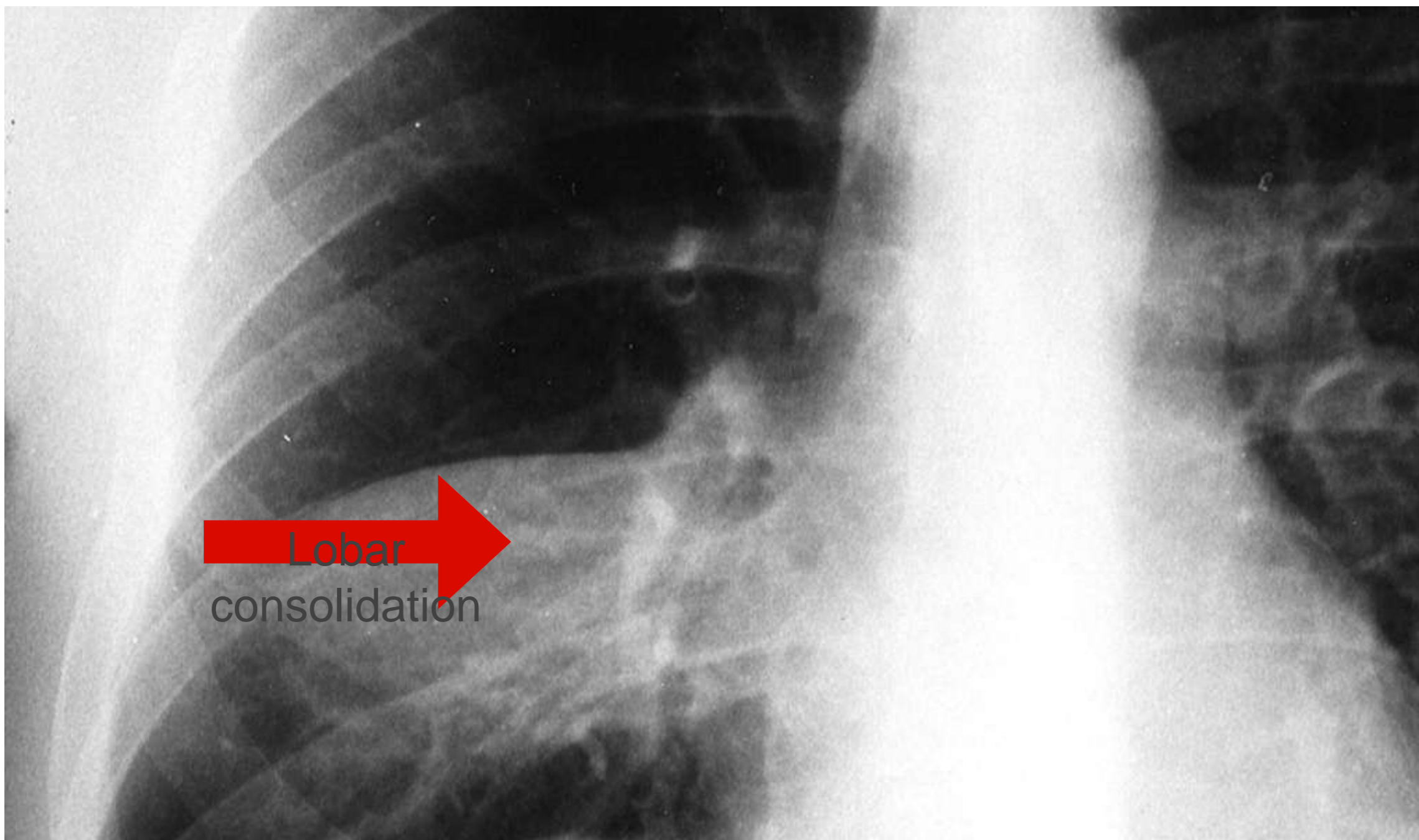
Left Lateral View



Right Lateral View

Intern Case

- 4 year old male with 2 weeks of cough, rhinorrhea and a one day history of tactile fevers, brought to the emergency department for increased WOB and hypoxia.
- Vitals Temp 38.8 HR 130 RR 40 BP 101/50 Pulse Ox 92%
- What are the top three diagnoses on your differential?
- Is it appropriate to obtain a Chest X-ray in this situation?
- What factors would support obtaining a Chest X-ray?
- What factors would deter you from obtaining a Chest X-ray?



What Do You See?

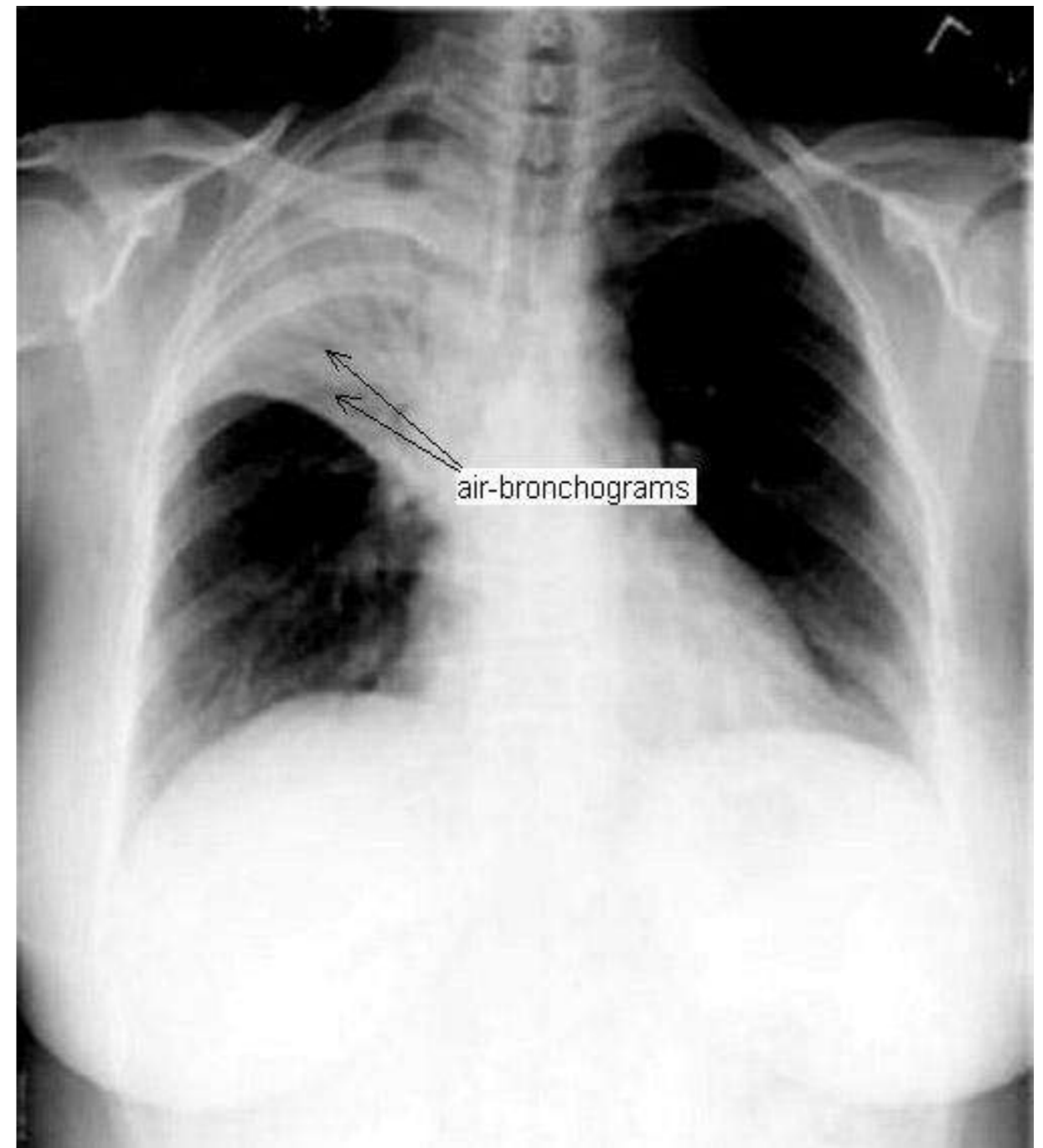
<http://radiology.rsna.org/content/210/2/339/F1.large.jpg>

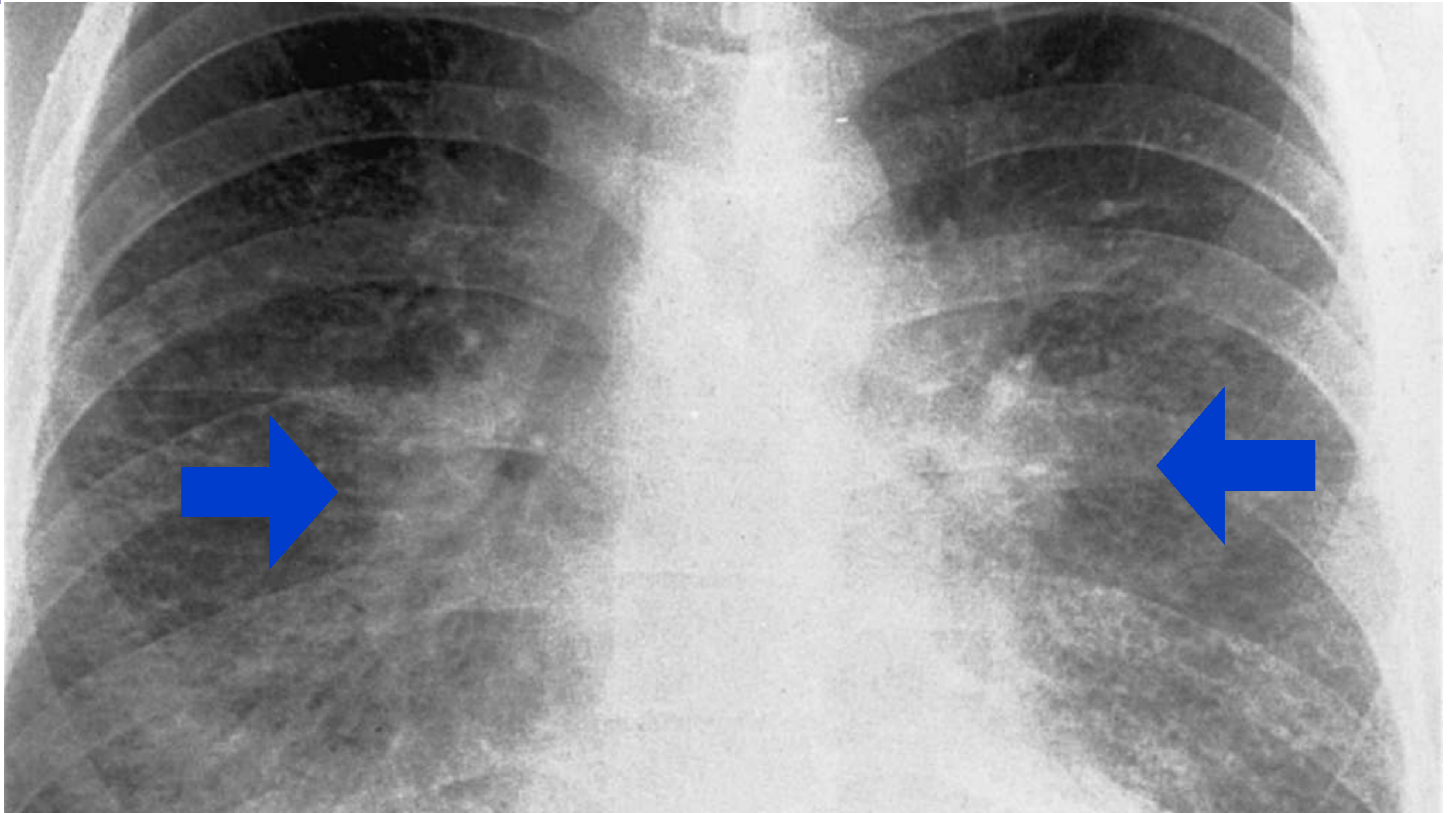
Radiographic Findings in Pneumonia

- Air bronchograms = most correlative
- New or worsening lung opacities
- Assymmetric focal findings
- Interstitial disease, especially in viral or atypical pneumonia
- Cavities, indicative of necrotizing pneumonia

Air Bronchograms

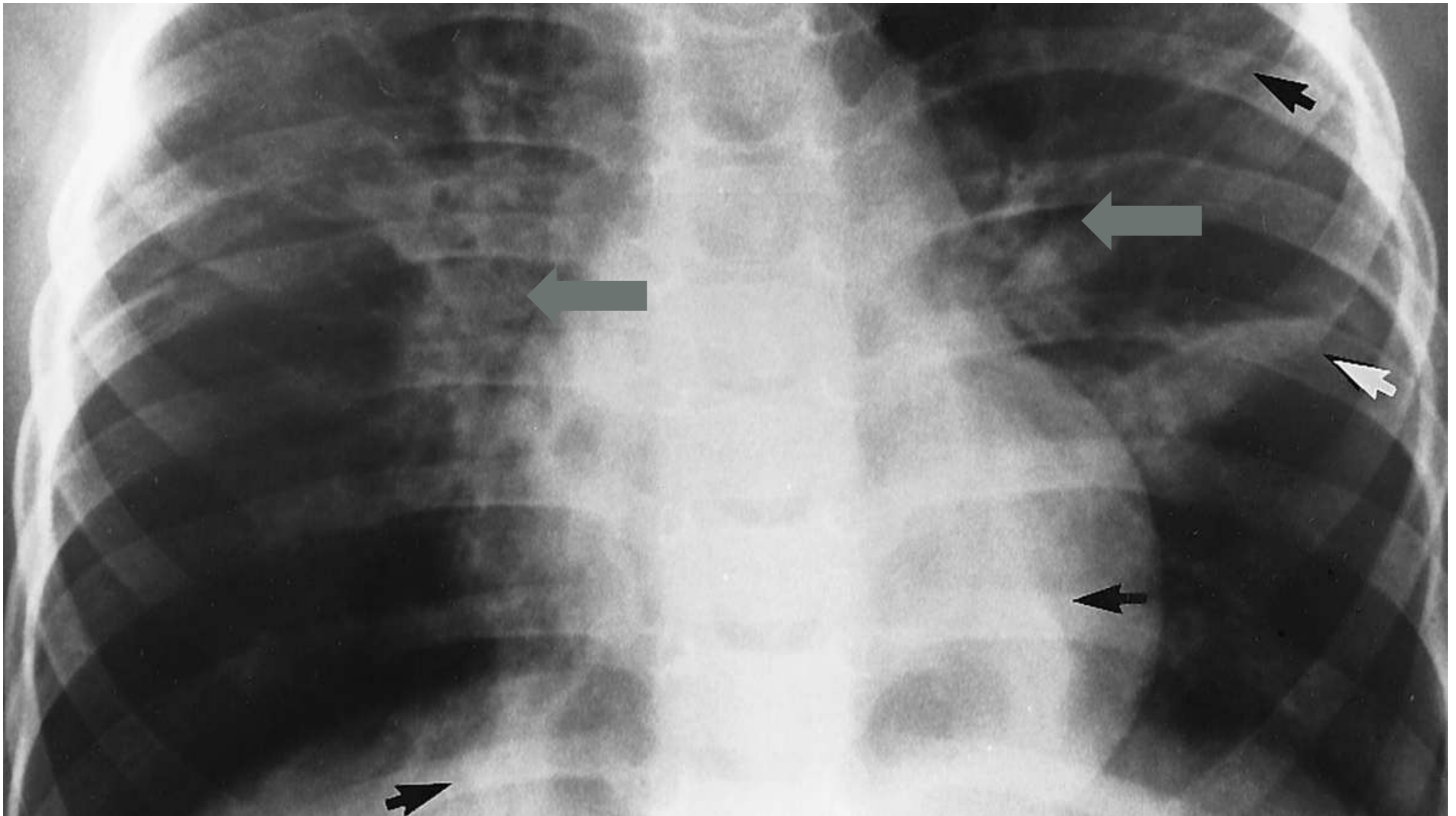
- Indicates airspace disease
- Visualized when an air-filled bronchus is surrounded by opacified alveoli
- Can be seen with :
 - pulmonary consolidation
 - pulmonary edema
 - non-obstructive atelectasis
 - severe interstitial disease
 - neoplasm
 - pulmonary infarction
 - normal expiration





Viral Pneumonia

http://radiographics.rsna.org/content/22/suppl_1/S137/F25.large.jpg

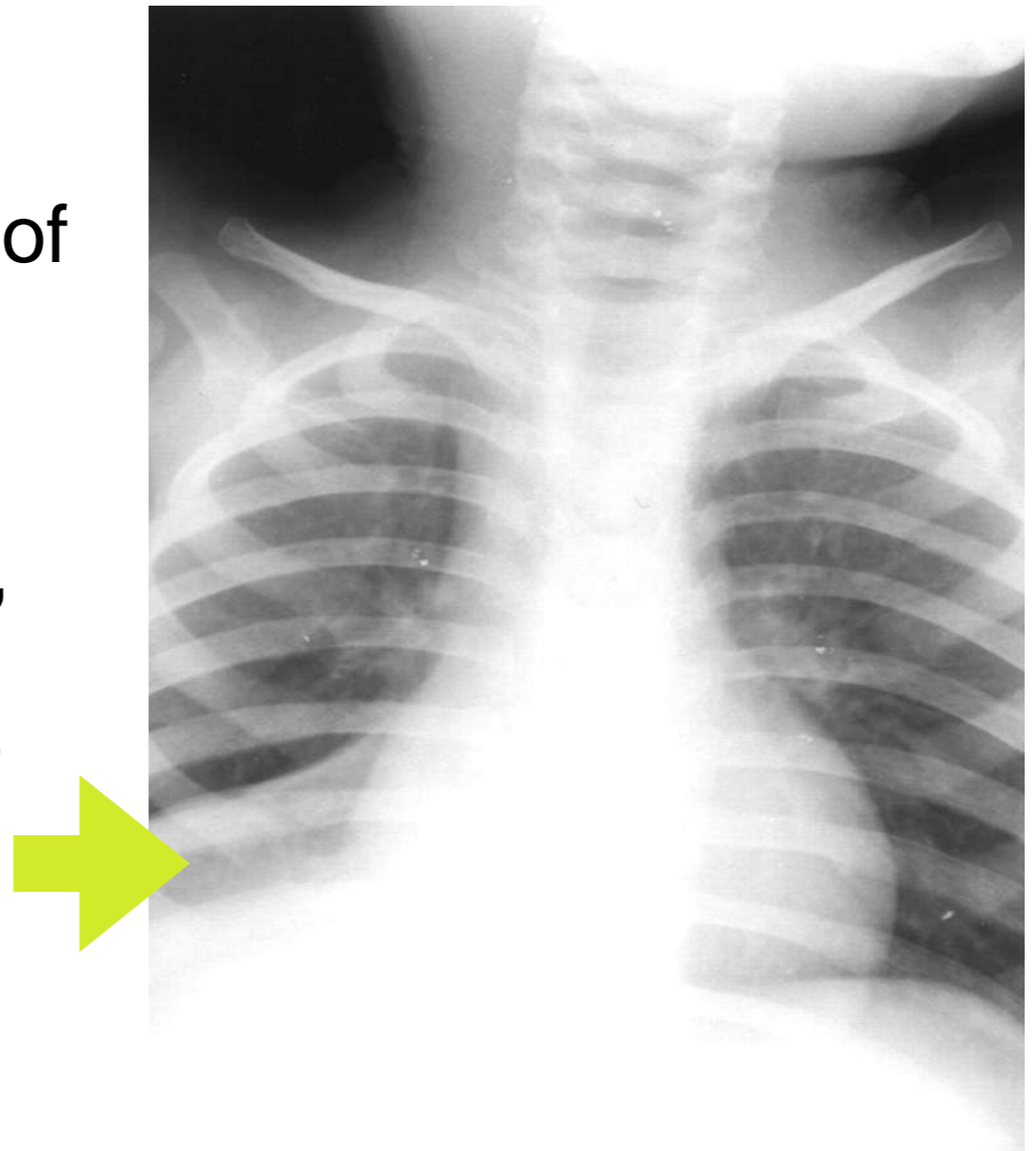


Atypical Pneumonia

<http://radiographics.rsna.org/content/21/1/121/F10.expansion>

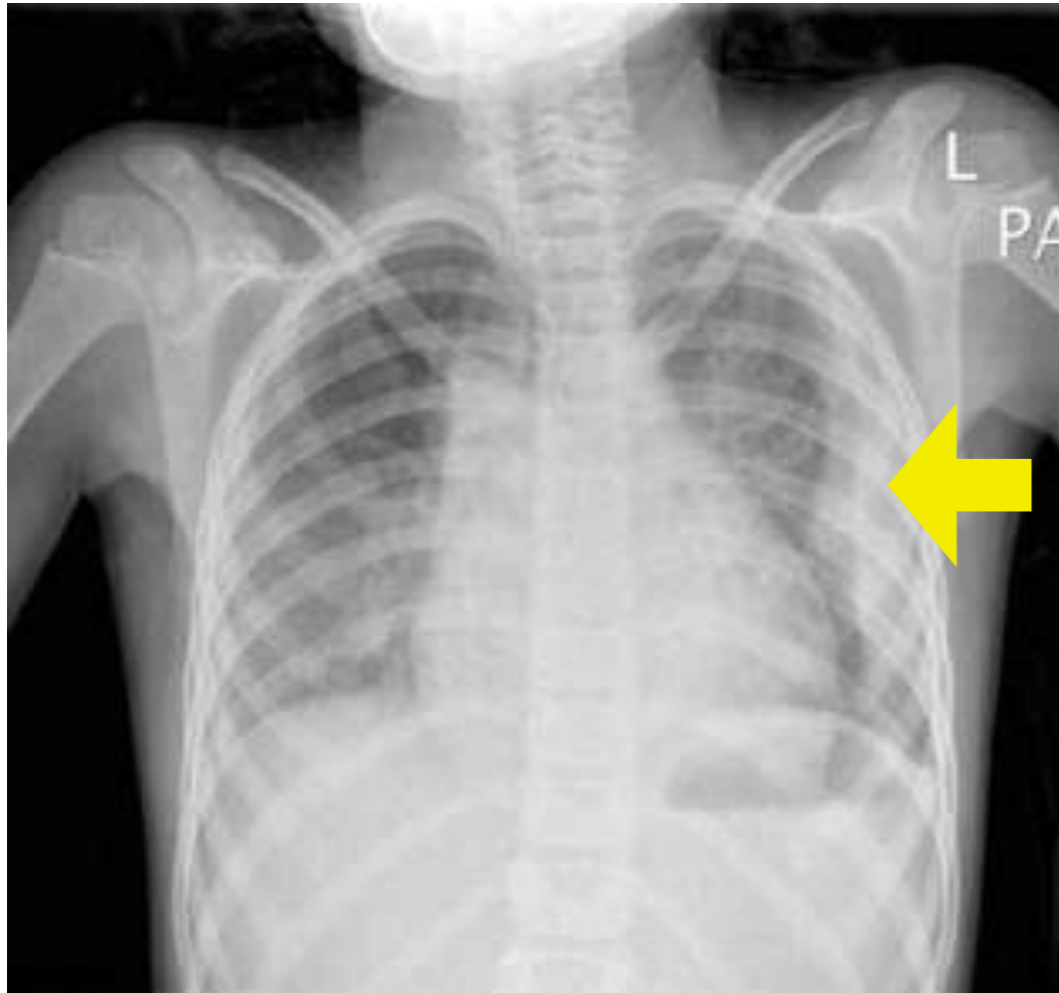
Atelectasis

- Volume loss with displacement of fissures
- White out of lobe or lung
- If large volume of lung involved, may get elevation of hemidiaphragm and displacement of mediastinal structures
- Radiographic findings resolve within hours to days



http://www.ajronline.org/content/vol183/issue6/images/large/12_03_0142_02A.jpeg

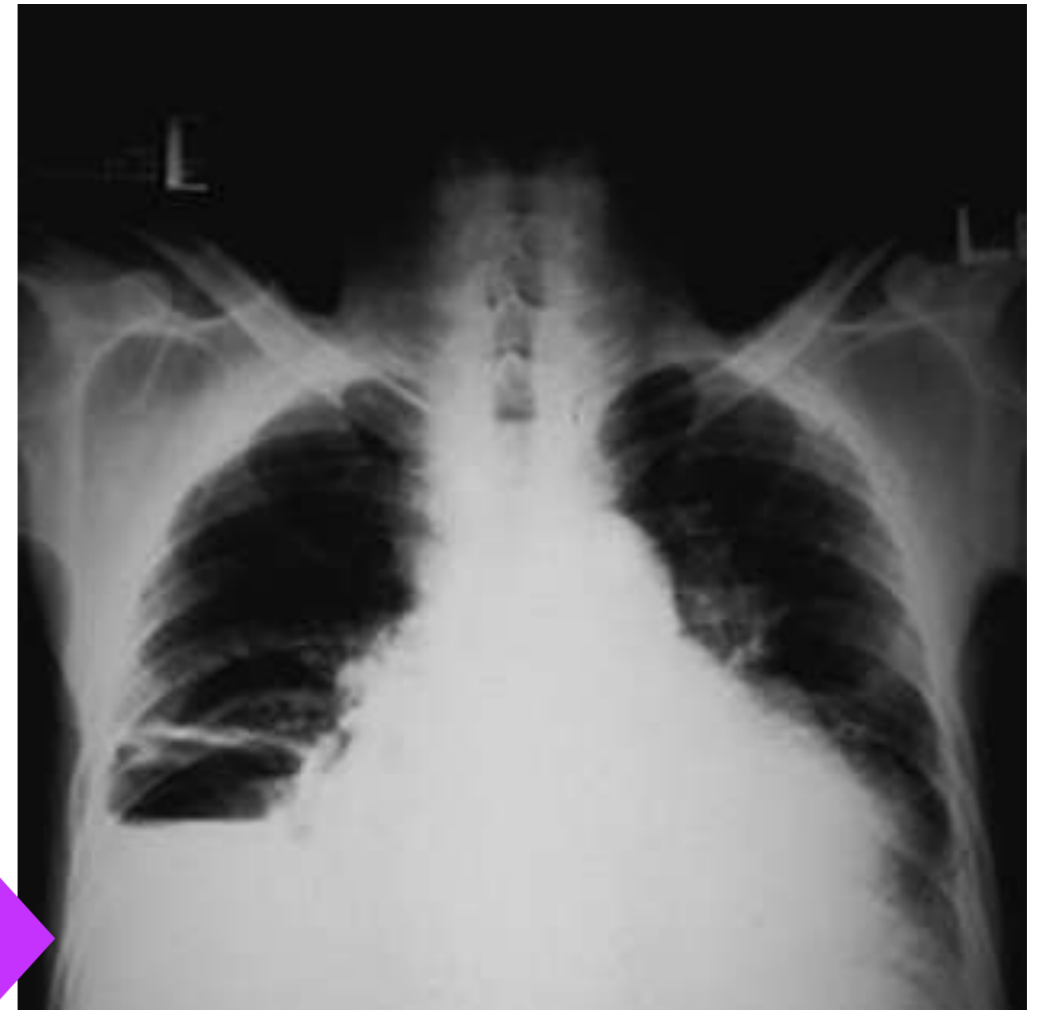Complications of Pneumonia on Chest



Pleural Effusion

- Appears as white density within lung field
- If not loculated, will layer out on lateral decubitus film

X-ray

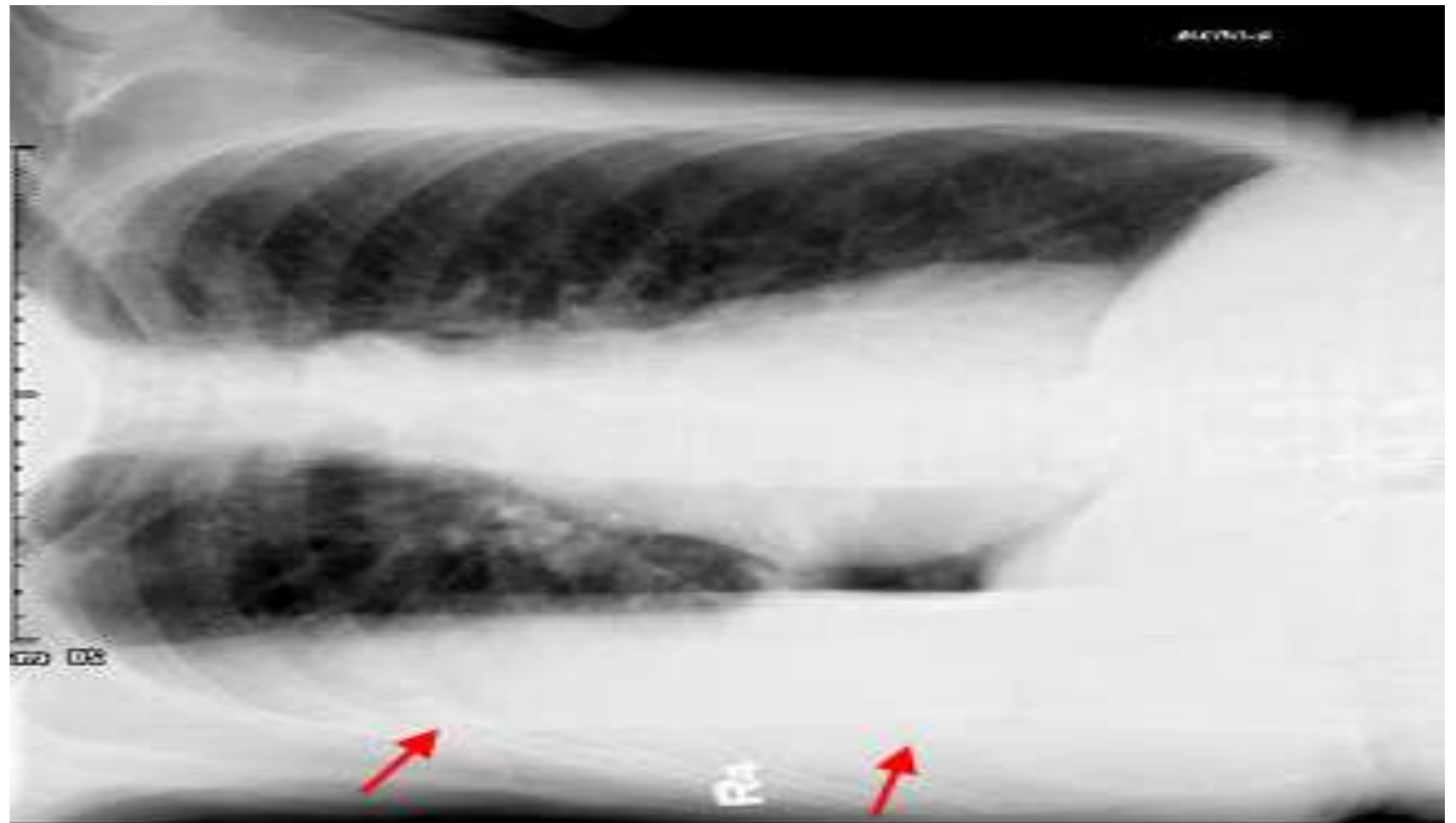


Empyema

- Appears as solid white consolidate that blunts the costophrenic angle
- May not layer out on lateral decubitus

Lateral Decubitus

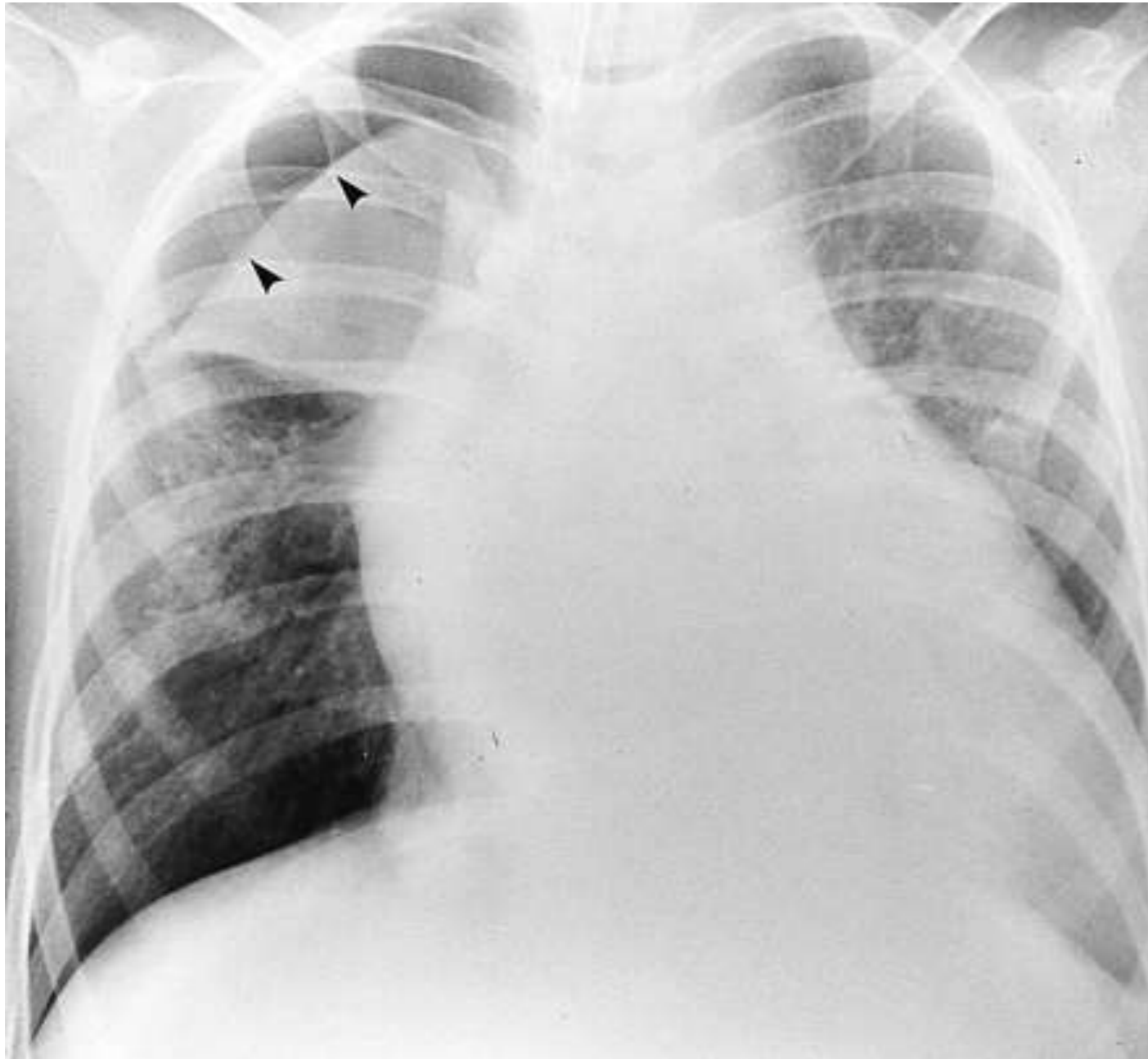
- Assess volume of pleural effusion
- Determine if effusion is mobile or loculated



<http://www.med-ed.virginia.edu/courses/rad/cxr/technique4chest.html>

Senior Case

- 12 year old tall thin male admitted overnight for monitoring after having a complicated eye surgery.
 - 3 Hours into your shift you receive a consult from Ophthalmology to evaluated the patient
 - He is complaining of a sharp, persistent chest pain and shortness of breath. You note on exam long fingers and thin skin
-
- What are the top three diagnoses on your differential?
 - Is a Chest X-ray Indicated?
 - Should it be ordered routine or stat?



What Do You See?

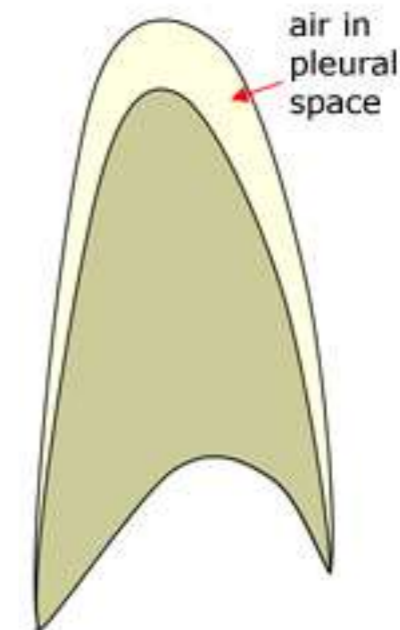
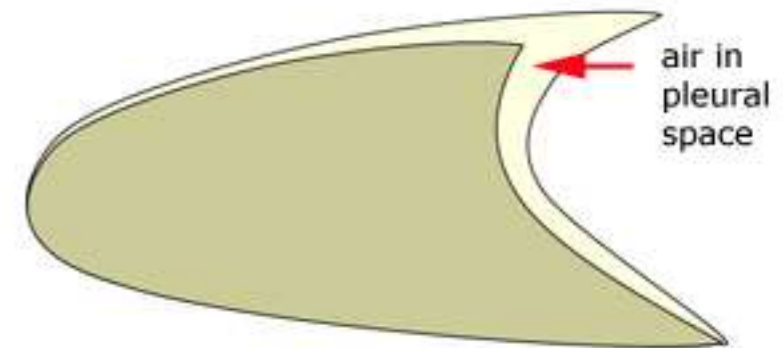
Note the lung is removed from borders of the pleural cavity

Area of lucency around diaphragm

<http://bjr.birjournals.org/cgi/content/full/74/877/89/F13>

Pneumothorax on Chest X-ray

- Consider if the X-ray is supine or erect
- Supine
 - Air tends to accumulate in the posterior chest wall
 - May appear near diaphragm first
- Erect
 - Air accumulates near the apices



Take Home Points

- A chest x-ray is a simple test that can be used in the diagnosis of many diseases.
- Pneumonia is a clinical diagnosis. Chest x-ray can be a useful tool to support the diagnosis and identify complications.
- When pneumothorax is suspected, chest x-ray should be obtained to determine its size and location and help guide management decisions.

References

- [Swischuk, E. Leonard. Emergency Imaging of the Acutely Ill or Injured Child. Lippencot Williams and Wilkins: Philadelphia, PA. 2000. Pages 71-88](#)
- [Behrman, Kliegman, Jenson. Nelsons Textbook of Pediatrics 17th edition. Atelectasis pp 1459-1461](#)
- Koumbourlis, AC. Albert Einstein College of Medicine, and Division of Pulmonary Medicine. Schneider Childrens Hospital, New Hyde Park, New York. Scoliosis and the Respiratory System. Paediatric Respiratory Review. 2006. Jun: 7(2):152-60. Epub 2006. Jun 2
- Schechter, MS. Airway Clearance Applications in infants and children. Respiratory Care. 2007. October: 52(10):1382-90
- Ilrena M. Tocino, M.D. Pneumothorax in the Supine Patient: Radiographic Anatomy. Radiographics Tocino 5 (4): 557. <http://radiographics.rsna.org/cgi/content/abstract/5/4/557> .
- Byung Gil Choi, MD. Seog Hee Park, MD. Eun Hee Yun, MD. Kyung Ok Chae, MD. Kyung Sub Shinn, MD Pneumothorax Size: Correlation of Supine Anteroposterior with Erect Posteroanterior Chest Radiographs. Radiology 1998; 209:567-569. <http://radiology.rsna.org/cgi/reprint/209/2/567>
- Dick, Elizabeth, *specialist registrar in radiology*, North Thames Deanery. Chest Xrays Made Easy. *studentBMJ* 2000;08:303-346 September ISSN 0966-6494.
- <http://lifeinthefastlane.com/education/investigations-tests/cxr-normal/>
- http://radiopaedia.org/articles/air_bronchogram
- http://en.wikipedia.org/wiki/Chest_radiograph
- Durbin, WJ and Stille, C Pneumonia. *Pediatr. Rev.* 2008; 29; 147-160
- Zaoutis, LB, Chiang, VW. Comprehensive Pediatric Hospital Medicine, 2007. Philadelphia, Elsevier.
- Kliegman, RM, Behrman, RE, Jenson, HB, Stanton, BF. Nelson Textbook of Pediatrics, 2007. Philadelphia, Elsevier.

References

- ACR Practice Guideline for the Performance of Pediatric and Adult Chest Radiography. Revised 2006. <http://www.acr.org/guidelines>
- Acute Respiratory Illness. ACR Appropriateness Criteria. Revised 2006. <http://www.acr.org/guidelines>
- Fever Without Source—Child. ACR Appropriateness Criteria. Revised 2006. <Http://www.acr.org/guidelines>
- Congestive Heart Failure. ACR Appropriateness Criteria. Revised 2006. <Http://www.acr.org/guidelines>
- Durbin, WJ and Stille, C Pneumonia. *Pediatr. Rev.* 2008; 29; 147-160
- Zaoutis, LB, Chiang, VW. *Comprehensive Pediatric Hospital Medicine*, 2007. Philadelphia, Elsevier.
- Kliegman, RM, Behrman, RE, Jenson, HB, Stanton, BF. *Nelson Textbook of Pediatrics*, 2007. Philadelphia, Elsevier.
- ACR Practice Guideline for the Performance of Pediatric and Adult Chest Radiography. Revised 2006. <http://www.acr.org/guidelines>
- Acute Respiratory Illness. ACR Appropriateness Criteria. Revised 2006. <http://www.acr.org/guidelines>
- Fever Without Source—Child. ACR Appropriateness Criteria. Revised 2006. <Http://www.acr.org/guidelines>
- Congestive Heart Failure. ACR Appropriateness Criteria. Revised 2006. <Http://www.acr.org/guidelines>
- <http://www.wikiradiography.com/page/The+Supine+Pneumothorax>
- <http://www.wikiradiography.com/page/Chest+Radiographic+Anatomy>